



Effects of Hydroxychloroquine and Tacrolimus on Discoid Facial Lupus Erythematosus in a Dog

Mykola Zhelavskiy¹ , Serhii Kernychnyi² , Tamara Betlinska² 

¹Vinnitsia National Agrarian University, Sonyachna Str., 3, Vinnitsia, 21008, Ukraine

²Higher educational institution Podillia State University, Shevchenko Str., 12, Kamyanets-Podilsky, 32302, Ukraine

*Corresponding author's Email: nicoladoctor@gmail.com

ABSTRACT

Discoid lupus erythematosus is an autoimmune disease that affects the skin in dogs. 6-year-old male German Shepherd weighing 38 kg was taken to the Small Animal Hospital at the University in Kyiv, Ukraine, with a history of progressive skin lesions. The indications of discoid lupus erythematosus in dogs manifested as red, scaly macules or papules on the skin's surface. These gradually develop into follicular plugging, disc-shaped plaques with adherent scales, and peripheral hyperpigmentation. The oral hydroxychloroquine was used for medication, and the prescribed dosage was 5.0 mg per kilogram of the dog's weight, administered once daily. The hydroxychloroquine was gradually reduced and discontinued within a month. Concurrent with the hydroxychloroquine treatment, the application of tacrolimus cream (Protopic® 0.03%) was initiated. The veterinary physician also advised the dog owner to limit sun exposure to avoid any adverse effects. After a four-week period, there was a decrease in pruritus and erythema, and plaques had flattened although the skin still had some patchy hyperpigmentation. Approximately 3-4 weeks later, the veterinarian determined that the dog had achieved clinical remission as all the skin lesions had become completely flattened. The use of deproteinized calf blood extract gel (Solcoseryl® Gel for external 4.15 mg/1 g, Legacy) led to the complete disappearance of the initial redness and prevented the appearance of new skin lesions. These results can be considered as a safe and effective alternative to conventional treatment methods.

Keywords: Dog, Discoid lupus erythematosus, Treatment

INTRODUCTION

The first description of the clinical manifestation of hitherto unknown skin disease in a dog that resembled human discoid lupus erythematosus was made in 1979 (Olivry et al., 2018; Marín-García and Lobat, 2022). Later, conflicting data regarding this dermatological pathology were found in the literature, which was reflected in the further improved nosological classification (Kuhn and Landmann, 2014). The first attempts to classify lupus erythematosus were based on the clinical pathology signs, such as systemic bullous type I form, exfoliative, and vesicular form of discoid lupus erythematosus (Salas and Kotschwar, 2014; Lecaros-Cornejo et al., 2015; Fukushima et al., 2021). Pathogenesis of the disease has complex mechanisms of development, which are still thoroughly studied by scientists from different countries of the world (Garelli et al., 2021). The etiology of discoid form lupus is multifactorial and includes environmental exposures, stochastic factors, and genetic susceptibility (Fernandes et al., 2016; Tham et al., 2020). Great progress has been made in understanding the pathogenesis of immune mechanisms (Banovic et al., 2017; Di Cerbo et al., 2021; Amudzi et al., 2022). To understand the mechanisms behind tissue damage and loss of tolerance, investigating lymphocyte signaling, phagocyte function, immune cell apoptosis, and interferon production pathways are crucial areas of study (Zhelavskiy, 2021). A better understanding of the pathogenesis of discoid form lupus has led to renewed interest in targeted therapy, and researchers are now on the cusp of developing targeted immunotherapy (Zhang et al., 2017; Zhelavskiy et al., 2020; Treeful et al., 2022).

Autoimmune reactions lead to the pathogenesis of lupus erythematosus. In a certain way, this creates certain difficulties for doctors in diagnosing and treating animals (Ferrigno et al., 2019; Zhou et al., 2021). The current study presented a novel approach to treating facial discoid lupus erythematosus (FDLE) in a German Shepherd dog, which has not been previously described in the veterinary literature.

MATERIALS AND METHODS

Ethical approval

The dog belonged to private owners, and written informed consent was obtained from them. Clinical studies were conducted in accordance with the Law of Ukraine "On Protection of Animals from Cruel Treatment" (No. 3447-IV of

CASE REPORT
pii: S232245682300039-13
Received: 05 April 2022
Accepted: 21 May 2023

February 21, 2006) and the requirements of the European Commission for the treatment of vertebrates and protection against thirst, hunger, malnutrition, discomfort, fear, pain, and suffering.

Case presentation

A 6-year-old male German Shepherd weighing 38 kg was brought to the Small Animal Hospital, Kyiv, Ukraine, due to developing skin lesions that gradually worsened. The research was conducted during May-June 2022. These nasal plaques initially appeared as itchy, scaly, erythematous lesions.

Despite conducting blood tests (morphological and biochemical) and numerous screenings for parasites and dermal mycosis, the underlying cause of the dog's clinical symptoms could not be identified. The dog was given various courses of medication, including corticosteroids (prednisolone at a dose of 4 mg/kg orally once a day) and enrofloxacin (4.0 mg/kg orally once daily), for 14 days, leading to some improvement. The clinical signs (hyperemia faces and pruritus) returned immediately upon discontinuation of therapy.

At the beginning of treatment and the dynamics of therapy, a detailed clinical examination of the patient was carried out. Parasitic diseases and dermatomycoses were not verified during the laboratory examination of slides obtained from the affected areas of the body. Treatment (determination of doses and duration of the course) was carried out on the basis of existing protocols (Gutfreund et al., 2013; Rossi et al., 2015). The originality of the research lies in the combination of drugs and the use of means for tissue regeneration.

The dog was given oral hydroxychloroquine (Plaquenil® Sanofi, France) at a dosage of 5.0 mg/kg once a day (Roxane Laboratories), which was gradually reduced and stopped over the course of a month. Concurrently, the dog was also treated with Crème tacrolimus (Protopic® 0.03% Crème, LEO Laboratories Limited, Denmark) and was advised to avoid excessive sun exposure (the cream was applied in a thin layer once a day). After four weeks, the dog's itchiness and redness had disappeared, and the plaques had flattened, although some mottled hyperpigmentation remained. Complete remission was estimated to have occurred in the following 3-4 weeks, as all skin lesions had completely flattened. The application gel deproteinized calf blood extract (Solcoseryl® Gel for external 4.15 mg/1 g, Legacy Pharmaceuticals Switzerland, GmbH) stimulated the disappearance of erythema and tissue repair.

Clinical signs

The initial skin lesions are characterized by redness and scaling, which gradually transform into disc-shaped plaques with attached scales, comedones, and darkening around the edges. These plaques combine, causing central scarring and loss of pigmentation (Ferrigno et al., 2019; Zhou et al., 2021). The initial skin manifestations in dogs involve erythema, loss of pigmentation, and scaling, which can advance to erosions with crust formation if the skin surface is disrupted. The lesions typically affect the nose, and dogs may also develop skin lesions on the upper back (Kuhn and Landmann, 2014; Olivry et al., 2018).

The dorsal nasal region was affected by partial baldness and consolidating annular to polycyclic, hyperpigmented plaques with fine silvery scaling (Figure 1 a). The central part of hyperpigmented lesions started to lose the normal skin texture. On the other hand, early skin lesions in canine FDLE typically involve scaling, depigmentation, and erythema, which then progress to erosions and ulcers that result in atrophy and loss of the nasal planum's structure (Figure 1 b). Crusting can occur when there is damage to epithelial integrity. Moreover, skin lesions can have an effect on the nasal planum. Starting from day 5, there was a gradual decrease in hyperemia of the wound and skin around the wound, itching, and pain reaction. From day 10 of treatment, a gradual epithelization of the wounds took place. Complete tissue regeneration was seen on day 30 (Figure 2).

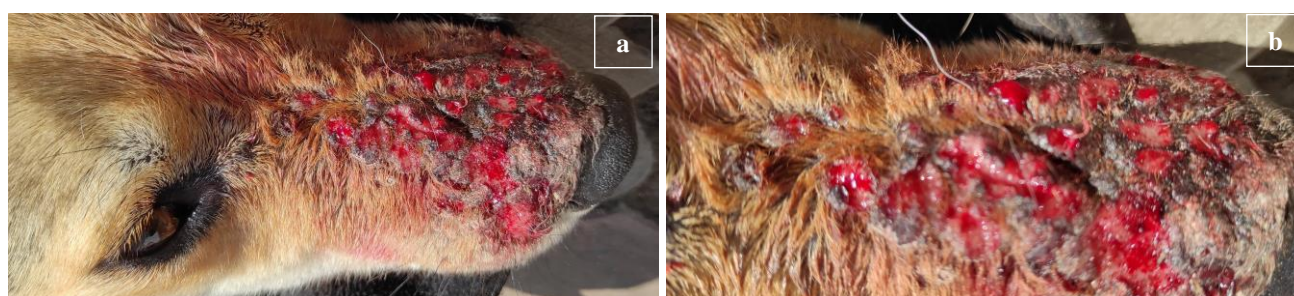

Figure 1. Clinical characteristics of canine facial discoid lupus erythematosus in a German Shepherd dog. **a:** Erythematous, depigmented, ulcerated, and crusted nasal lesions of facial; **b:** Complete loss of cobblestone appearance is visible (magnification 2.5)

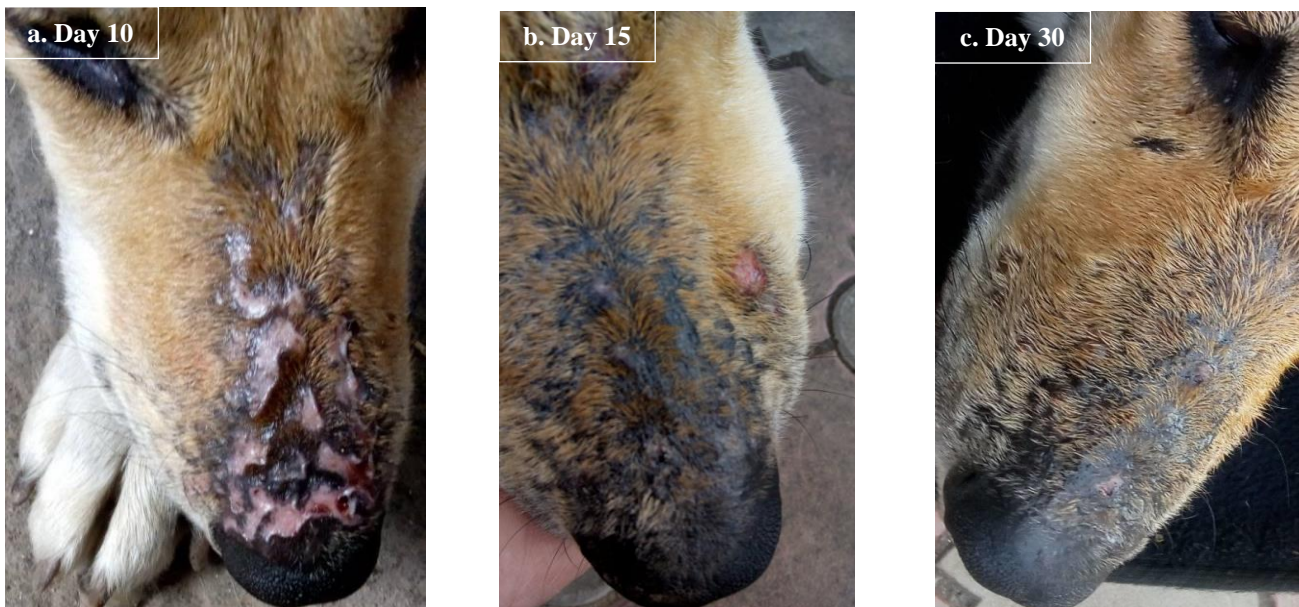


Figure 2. Clinical changes during the treatment of a German Shepherd dog; Starting from day 5, hyperemia of the wound and skin around the wound, itching, and pain reaction gradually decreased. **a:** A gradual epithelization from day 10 of treatment, **b:** Wound healing (day 15), **c:** Tissue repair on day 30

DISCUSSION

Over the past decades, there have been accumulated data on the diagnosis and treatment of canine FDLE in dogs. There are more and more data on immunogenetic factors and the manifestation of autoimmune reactions in this pathology (Chong et al., 2022). Despite this, veterinarians are actively searching for effective methods and means of treatment. For the most part, therapy focuses on the use of drugs that have an immunosuppressive effect. Earlier research has indicated that immunosuppressive doses of corticosteroids are effective in treating patients with discoid lupus erythematosus (Hyun et al., 2021). It has been suggested that the combination of tetracycline and niacinamide, with or without corticosteroids, may be a viable treatment combination (Rossi et al., 2015). In the treatment of discoid lupus erythematosus, cyclosporine (a systemic calcineurin inhibitor) has been administered either as a monotherapy or in combination with glucocorticoids (Banovic et al., 2014). Topical application of tacrolimus has been found to be an effective treatment for autoimmune skin conditions (Gutfreund et al., 2013). The use of tacrolimus in discoid lupus erythematosus of dogs has been reported (Hyun et al., 2021).

The gel form of solcoseryl, a medication derived from protein-free dialysate from calf blood, was applied as a treatment. Solcoseryl increased adhesion, migration, proliferation, and wound healing (Martí-Carvajal et al., 2014).

Open sources provide limited information on the use of solcoseryl in clinical practice. Fragmentary reports are available regarding the treatment of patients with corneal lesions and dermatological problems (Nam and Maen, 2019). The positive dynamics of treatment give prospects for the combined use of drugs (hydroxychloroquine, tacrolimus, and solcoseryl gel) with discoid lupus erythematosus in canis.

In this case, the proposed therapy can be used by clinicians for the therapy of discoid facial lupus erythematosus in dogs. Further research and the development of pharmacology will be an excellent impetus for the development of effective treatments.

CONCLUSION

The treatment of clinical features of facial discoid lupus erythematosus by hydroxychloroquine, tacrolimus, and gel deproteinized calf blood extract ointment in a German Shepherd dog had successful results. No drug-related side effects were seen. These results can be considered in the treatment of facial discoid lupus erythematosus and suggested to be an alternative to previous standard treatments.

DECLARATIONS

Acknowledgments

This article is a part of the classes of the Academy of Sciences, Higher School of Ukraine.

Funding

The present study had no financial support.

Competing interests

There is no conflict of interest.

Ethical consideration

The authors considered all necessary ethical issues (e.g., plagiarism, consent to publish, misconduct, data fabrication and/or falsification, double publication and/or submission, and redundancy).

Authors' contributions

Mykola Zhelavskiy conceived of the presented idea. Mykola Zhelavskiy and Serhii Kernychnyi verified medical history, contributed to data, carried out the experiment, wrote a manuscript, and prepared the article for submission. Tamara Betlinska participated in its design and coordination and helped to draft the manuscript. All authors read and approved the final manuscript.

REFERENCES

- Amudzi AA, Piedra-Mora C, Ma DJ, Wong NB, David CN, Robinson NA, Almela RM, and Richmond JM (2022). Using gene expression analysis to understand complex autoimmune skin disease patients: A series of four canine cutaneous lupus erythematosus cases. *Frontiers in Veterinary Science*, 9: 778934. DOI: <https://www.doi.org/10.3389/fvets.2022.778934>
- Banovic F, Olivry T, and Linder KE (2014). Ciclosporin therapy for canine generalized discoid lupus erythematosus refractory to doxycycline and niacinamide. *Veterinary Dermatology*, 25(5): 483-e79. DOI: <https://www.doi.org/10.1111/vde.12139>
- Banovic F, Robson D, Linek M, and Olivry T (2017). Therapeutic effectiveness of calcineurin inhibitors in canine vesicular cutaneous lupus erythematosus. *Veterinary Dermatology*, 28(5): 493-e115. DOI: <https://www.doi.org/10.1111/vde.12448>
- Chong E, Austel M, and Banovic F (2022). A retrospective evaluation of the steroid-sparing effect of oral modified cyclosporin for treatment of canine pemphigus foliaceus. *Veterinary Sciences*, 9(4): 153. DOI: <https://www.doi.org/10.3390/vetsci9040153>
- Di Cerbo A, Giusti S, Mariotti F, Spaterna A, Rossi G, and Magi GE (2021). Increased expression of toll-like receptor 4 in skin of dogs with discoid lupus erythematosus (DLE). *Animals*, 11(4): 1044. DOI: <https://www.doi.org/10.3390/ani11041044>
- Fernandes M, Rosa N, Esteves E, Correia MJ, Arrais J, Ribeiro P, Vala H, and Barros M (2016). CanisOme--the protein signatures of canis lupus familiaris diseases. *Journal of Proteomics*, 136: 193-201. DOI: <https://www.doi.org/10.1016/j.jprot.2016.01.005>
- Ferrigno A, Hoover K, Blubaugh A, Rissi D, and Banovic F (2019). Treatment of exfoliative cutaneous lupus erythematosus in a German shorthaired pointer dog with mycophenolate mofetil. *Veterinary Dermatology*, 30(4): 350-e102. DOI: <https://www.doi.org/10.1111/vde.12747>
- Fukushima K, Lappin M, Legare M, and Veir J (2021). A retrospective study of adverse effects of mycophenolate mofetil administration to dogs with immune-mediated disease. *Journal of Veterinary Internal Medicine*, 35(5): 2215-2221. DOI: <https://www.doi.org/10.1111/jvim.16209>
- Garelli CJ, Wong NB, Piedra-Mora C, Wrijil LM, Scarglia G, David CN, Almela RM, Robins NA, and Richmond JM (2021). Shared inflammatory and skin-specific gene signatures reveal common drivers of discoid lupus erythematosus in canines, humans and mice. *Current Research in Immunology*, 2: 41-51. DOI: <https://www.doi.org/10.1016/j.crimmu.2021.03.003>
- Gutfreund K, Bienias W, Szewczyk A, and Kaszuba A (2013). Topical calcineurin inhibitors in dermatology. Part I: Properties, method and effectiveness of drug use. *Advances in Dermatology and Allergology*, 30(3): 165-169. DOI: <https://www.doi.org/10.5114/pdia.2013.35619>
- Hyun JE, Kang YH, and Hwang CY (2021). Successful treatment of mucocutaneous lupus erythematosus in a dog with prednisolone, mycophenolate mofetil and tacrolimus. *Veterinary Sciences*, 8(5): 72. DOI: <https://www.doi.org/10.3390/vetsci8050072>
- Kuhn A and Landmann A (2014). The classification and diagnosis of cutaneous lupus erythematosus. *Journal of Autoimmunity*, 48-49: 14-19. DOI: <https://www.doi.org/10.1016/j.jaut.2014.01.021>
- Lecaros-Cornejo C, Lecaros-Cornejo C, and Díaz S (2015). Lupus eritematoso cutáneo canino: Algunas consideraciones acerca de la cercanía humana con los animales [Cutaneous lupus erythematosus in a dog: Reflections on human-animal evolutionary connections]. *Revista medica de Chile*, 143(3): 405-407. DOI: <https://www.doi.org/10.4067/S0034-98872015000300020>
- Marín-García PJ and Llobat L (2022). Inheritance of monogenic hereditary skin disease and related canine breeds. *Veterinary Sciences*, 9(8): 433. DOI: <https://www.doi.org/10.3390/vetsci9080433>
- Martí-Carvajal AJ, Knight-Madden JM, and Martínez-Zapata MJ (2014). Interventions for treating leg ulcers in people with sickle cell disease. *The Cochrane Database of Systematic Reviews*, 2014(12): CD008394. DOI: <https://www.doi.org/10.1002/14651858.CD008394.pub3>
- Nam SM and Maen YS (2019). Wound healing and mucin gene expression of human corneal epithelial cells treated with deproteinized extract of calf blood. *Current Eye Research*, 44(11): 1181-1188. DOI: <https://www.doi.org/10.1080/02713683.2019.1633360>
- Olivry T, Linder KE, and Banovic F (2018). Cutaneous lupus erythematosus in dogs: A comprehensive review. *BMC Veterinary Research*, 14(1): 132. DOI: <https://www.doi.org/10.1186/s12917-018-1446-8>

- Rossi MA, Messenger LM, Linder KE, and Olivry T (2015). Generalized canine discoid lupus erythematosus responsive to tetracycline and niacinamide therapy. *Journal of the American Animal Hospital Association*, 51(3): 171-175. DOI: <https://www.doi.org/10.5326/JAAHA-MS-6116>
- Salas EN and Kotschwar JL (2014). Pathology in practice. Exfoliative cutaneous lupus erythematosus in a German Shorthaired Pointer. *Journal of the American Veterinary Medical Association*, 245(3): 291-293. DOI: <https://www.doi.org/10.2460/javma.245.3.291>
- Tham HL, Linder KE, and Olivry T (2020). Deep pemphigus (pemphigus vulgaris, pemphigus vegetans and paraneoplastic pemphigus) in dogs, cats and horses: A comprehensive review. *BMC Veterinary Research*, 16(1): 457. DOI: <https://www.doi.org/10.1186/s12917-020-02677-w>
- Treeful AE, Coffey EL, and FriedenberG SG (2022). A scoping review of autoantibodies as biomarkers for canine autoimmune disease. *Journal of Veterinary Internal Medicine*, 36(2): 363-378. DOI: <https://www.doi.org/10.1111/jvim.16392>
- Zhang YP, Wu J, Han YF, Shi ZR, and Wang L (2017). Pathogenesis of cutaneous lupus erythema associated with and without systemic lupus erythema. *Autoimmunity Reviews*, 16(7): 735-742. DOI: <https://www.doi.org/10.1016/j.autrev.2017.05.009>
- Zhelavskiy MM (2021). The role of neutrophil on subclinical mastitis in cows. *Polish Journal of Natural Sciences*, 36(1): 107-115. Available at: <http://www.uwm.edu.pl/polish-journal/sites/default/files/issues/articles/07-zhelavskiy.pdf>
- Zhelavskiy MM, Shunin IM, and Midyk SV (2020). Extracellular antibacterial defense mechanisms of neutrophil granulocytes and their role in pathogenesis of pyometra (cases) in cats. *Polish Journal of Natural Sciences*, 35(3): 363-378. Available at: <http://www.uwm.edu.pl/polish-journal/sites/default/files/issues/articles/09-zhelavsky.pdf>
- Zhou Z, Corner S, Petersen A, Rosser E, and Noland EL (2021). Clinical presentation, treatment, and outcome in dogs with pemphigus foliaceus with and without vasculopathic lesions: An evaluation of 41 cases. *Veterinary Dermatology*, 32(5): 503-e139. DOI: <https://www.doi.org/10.1111/vde.12996>

Publisher's note: [Scienceline Publication](#) Ltd. remains neutral with regard to jurisdictional claims in published maps and institutional affiliations.



Open Access: This article is licensed under a Creative Commons Attribution 4.0 International License, which permits use, sharing, adaptation, distribution and reproduction in any medium or format, as long as you give appropriate credit to the original author(s) and the source, provide a link to the Creative Commons licence, and indicate if changes were made. The images or other third party material in this article are included in the article's Creative Commons licence, unless indicated otherwise in a credit line to the material. If material is not included in the article's Creative Commons licence and your intended use is not permitted by statutory regulation or exceeds the permitted use, you will need to obtain permission directly from the copyright holder. To view a copy of this licence, visit <https://creativecommons.org/licenses/by/4.0/>.

© The Author(s) 2023