







ANTIOXIDANT ACTIVITY OF RAW AND COOKED ONIONS IN RABBIT DOE NUTRITION

Ammar Abdulrazzaq TAWFEEQ^{1*}   , Entisar Nadhim SHALLAL¹ , Ali M ABDULWAHID²  and Bilal J M ALDAHHAM¹ 

¹College of Applied Sciences, University of Anbar, Heet, Iraq

²Iraqi Ministry of Health, Anbar Health Department, Heet General Hospital, Iraq

*Email: ammarabta@uoanbar.edu.iq

*Supporting Information

ABSTRACT: The aim of this research is to examine how raw and cooked onions affect some antioxidant enzymes and some tissues in female rabbits. Twenty-four female albino rabbits weighing (1-1.5 Kg), (5-6 months age), non-pregnant, were used for the experiment, and they were divided into three groups for a duration of 28 days. A 20 g/kg raw onion and same amount of cooked onion were added to the second and third groups' diets respectively for comparison of results with control groups without any addition of onion. Results showed that diets supplemented with raw and cooked onion significantly increased the superoxide dismutase (SOD) activity. The cooked onion group showed normal and no pathological changes in liver, kidney, and heart tissues, while liver tissues of both control and raw onion groups suffered extreme congestion in the central veins of the liver lobules and in kidney tissues of only control rabbits, developed hemorrhagic foci was observed. In the control and raw onion groups, the heart tissue showed the development of hemorrhagic foci and necrosis in the heart muscle fibers. In conclusion, both raw and cooked onions boosted the activity of SOD enzyme, but the cooked onions showed to be more effective than raw at protecting liver, kidney, and heart tissues against cell necrosis caused by oxidative processes.

Keywords: Cooked onion, Oxidative stress, Rabbits, Superoxide dismutase, Tissue.

INTRODUCTION

Many biologically active compounds are found in onions, including organosulfur compounds, thiosulfates, and polyphenols, which include flavonoids and fructooligosaccharides. Anthocyanins, quercetin, and quercetin derivatives are among the most biologically active flavonoids (Bystrická et al, 2013; Sagar et al, 2022). The biological activity of these compounds is important for preventing cell damage caused by free radicals and oxidative stress, which can lead to serious diseases such as cancer (Alpsoy et al, 2013). These compounds also have other important biological activities, such as antimicrobial, anti-diabetic, and other physiological activities (Kumar et al, 2022). Cooking onions causes fundamental changes in their structure, which increases the extractability of phenolic compounds due to the decomposition of cell walls and the release of phenolic compounds bound to fibers (Cattivelli et al, 2021).

The highest concentration of phenolic compounds was found in barbecue onions, followed by baked, boiled, and fried onions, and it was discovered (Cattivelli et al, 2022) that all heat treatments of onions increased the total phenolic compounds when compared with raw onions. Barbecue was also found to be the heat treatment that was able to preserve anthocyanins after digestion in the laboratory. Another study found that the concentration of Quercetin increased when onions were baked or fried, but decreased when they were cooked by boiling (Lombard et al 2005). According to Sans et al (2019), roast onion increased the concentration of most nutrients except for fiber and the total content of phenols, flavonoids, calcium, sodium, and iron, which decreased after grilling, but increased the antioxidant activity of onions. They compared roasted onions to raw onions after *in vitro* gastric digestion and attributed the increase in antioxidant activity to the release of antioxidant compounds from insoluble parts or the formation of new compounds with antioxidant properties during the cooking process.

Numerous earlier studies focused on the beneficial effects of raw onions and the active ingredients they contain in the field of veterinary medicine, particularly the antioxidant properties. According to Sabir et al (2019), adding onion juice or powder to the diet of male rabbits caused a substantial increase in the levels of superoxide dismutase and total antioxidant capacity as well as a significant decrease in malondialdehyde in serum when compared to control rabbits. Additionally, treatment of onion aqueous extract to diabetic rabbits enhanced catalase, superoxide dismutase, and glutathione peroxidase levels while decreasing glutathione and malondialdehyde levels in the liver (Ogunmodede et al, 2012). Previous studies lack a comparison between the effect of raw and cooked onions on the tissues of the liver, kidneys, stomach and heart, and because the protection of the mentioned tissues is linked to the mechanisms of anti-

RESEARCH ARTICLE
 PII: S222877012300021-13
 Received: February 6, 2023
 Revised: March 27, 2023
 Accepted: March 28, 2023

oxidation, so it is necessary to follow up the essential anti-oxidant enzymes while adding both types of onions to the ration.

The aim of this study is to evaluate the efficacy of cooking onions on the level of antioxidant enzymes in the blood serum, as well as the protective role it plays by protecting cells in the rabbit liver, kidneys, heart, and stomach from oxidative stress-induced damage.

MATERIALS AND METHODS

Twenty-four female rabbits (Albino), with a weight (1-1.5 Kg), (5-6 months age), non-pregnant, have been chosen to reveal the effect of cooked onions on their tissues. The rabbits were divided into three groups, with eight rabbits in each group. The first group was used as a control group. The diet of the second group was supplemented with 20g/ Kg of raw onions, while the third group's diet was supplemented with 20g/ Kg of cooked onions.

The onions were obtained from a local market. They were washed and the external shells were removed. The internal shell was cut into small pieces and was divided into two parts. The first one was added directly to the diet while the second one was boiled for 15 minutes before being added to the diet of the third group.

In order to measure the characteristics of whole blood using the Auto Analyzer of Blood provided by (IRMA company, Japan), 5 ml of blood from each rabbit's heart was taken directly after the experiment. This blood was then divided into two tubes, the first of which contained an anticoagulant (Ethylenediaminetetraacetic acid - EDTA). For the aim of evaluating the levels of lipid index components and the activity of antioxidant enzymes, including Total Superoxide Dismutase, Glutathione Peroxidase and Xanthine Oxidase (Paglia and Valentine, 1967; Stripe et al, 1969), the second tube is free of any anticoagulant substance and is used to centrifuge the serum from the cellular portion of the blood (Paoletti and Mocali, 1990).

Statistical analysis

Data were analyzed by one-way analysis of variance, using the general linear model (GLM) procedures of SAS. The significant differences among the means were tested by Duncan's multiple range test at probability value ($p \leq 0.05$; Duncan, 1955).

Ethical approval

According to Directive 2010/63/EU of 22 September 2010, and recommendation of the European Commission 2007/526/CE, the animal in the current study were used for experimental and other scientific purposes.

RESULTS

According to the findings in Table 1, there were no significant differences among all tested blood parameters for the groups under study. The same appears to be the case for the results presented in Table 2, which show that there are no notable variations in the characteristics of the fat index among the groups under study.

The activity of the superoxide dismutase enzyme in the blood serum is much higher in the rabbits from the two groups of raw and cooked onions than it is in the rabbits from the control group, as shown in Figure 1. The levels of the enzymes xanthine oxidase and glutathione peroxidase in the blood serum did not significantly differ across research groups. In the control group of rabbits, histological sections of the liver demonstrated severe congestion in the sinusoids with severe hydronephrosis and enlargement of hepatocytes in the hepatic lobule area, as well as the central veins of the liver lobules and the portal area. Additionally, it was discovered that the liver tissue of the rabbits in the raw onion group exhibited swollen hepatocytes, watery overall degeneration, and congestion in the central and portal veins of the liver lobules. On the other hand, the cooked onion group's liver tissue showed some slight congestion in the central veins of the liver lobules with regularity of the shape of hepatic lobule and the hepatocyte ropes. At the same time, the shape of most of the cells appeared normal with the appearance of simple water degeneration in a few of them as in Figure 2, the cooked onion group's liver tissue in rabbits showed no such congestion.

The histological sections of the kidneys in the control rabbits showed the formation of multiple hemorrhagic foci in the inter-renal cortex tissue. Along with a general clouded degeneration of the renal tubules, it also appeared as though the renal tubules were obviously enlarged. On the other hand, in the cortex and pulp of the kidneys of the raw onion group rabbits, the renal tubules and glomeruli had a normal look, with a small congestion of the arteries between the renal tubules. While the kidney cortex and pulp histological sections in the cooked onion group of rabbits did not exhibit any pathological alterations and appeared normal (Figure 3).

Figure 4 illustrates the histological section of heart in different groups. Pictures of cooked onion group appeared normal and did not show any pathological changes compared to other study groups as suffering from coagulative necrosis and clots within cardiac cavities in control groups and group of crude onion suffered from large, severe hemorrhage with edema, atrophy, and foci of necrotic and degenerative myocardium. The rabbits in the three groups' stomach mucosa histological sections displayed a normal appearance and bore no signs of pathological alterations (Figure 5).

Table 1 - Effect of raw and cooked onion on the hematological blood tests in rabbits

Item	Control	Raw onion	Cooked onion	P-value
WBC (thousand cell/ml ³)	4.62 ± 0.852	4.80 ± 1.11	15.7 ± 9.20	N.S.
Lymphocytes%	57.3 ± 5.42	57.4 ± 8.51	62.6 ± 9.01	N.S.
Monocytes%	9.41 ± 1.23	10.8 ± 1.10	6.38 ± 1.28	N.S.
Granulocytes%	33.2 ± 4.85	31.7 ± 7.61	31.0 ± 8.32	N.S.
Lymphocytes	2.48 ± 0.456	2.60 ± 0.633	12.0 ± 9.93	N.S.
Monocytes	0.387 ± 0.093	0.500 ± 0.147	0.380 ± 0.198	N.S.
Granulocytes	1.75 ± 0.386	1.70 ± 0.484	2.06 ± 1.06	N.S.
RBC (million cell/ml ³)	6.68 ± 0.713	5.75 ± 0.447	5.76 ± 1.31	N.S.
HGB (gm/100 ml)	10.6 ± 1.28	9.82 ± 0.539	10.8 ± 1.25	N.S.
HCT %	43.5 ± 4.76	36.9 ± 2.64	44.5 ± 6.10	N.S.
MCV	65.1 ± 0.742	64.2 ± 1.03	66.8 ± 1.47	N.S.
MCH	15.4 ± 0.729	17.1 ± 0.545	16.5 ± 0.797	N.S.
MCHC	23.7 ± 1.20	26.6 ± 0.512	24.8 ± 1.35	N.S.
RDW	13.3 ± 0.286	13.5 ± 0.476	13.5 ± 0.294	N.S.
PLT (thousand cell/ml ³)	401 ± 106	401 ± 118	285 ± 99.8	N.S.
MPV	6.90 ± 0.403	6.62 ± 0.460	6.48 ± 0.284	N.S.
PCT %	0.263 ± 0.067	0.250 ± 0.070	0.184 ± 0.063	N.S.
PDW	7.67 ± 0.994	8.07 ± 0.828	8.01 ± 0.695	N.S.

Mean ± Standard Error. N.S.: Non-Significant at probability value (P≤0.05).

Table 2 - Effect of raw and cooked onion on the lipid profile in serum of rabbits

Item	Control	Raw onion	Cooked onion	P-value
Cholesterol (mg/dl)	51.7 ± 6.32	54.7 ± 8.33	43.5 ± 15.3	N.S.
Triglyceride (mg/dl)	147 ± 33.9	139 ± 49.7	81.0 ± 15.2	N.S.
High Density Lipoprotein (mg/dl)	9.12 ± 1.18	6.87 ± 1.73	6.03 ± 1.62	N.S.
Low Density Lipoprotein (mg/dl)	17.6 ± 6.03	20.0 ± 3.87	25.8 ± 15.8	N.S.
Very Low Density Lipoprotein (mg/dl)	29.5 ± 6.74	27.7 ± 10.1	16.1 ± 3.08	N.S.

Mean ± Standard Error. N.S.: Non-Significant at probability value (P≤0.05).

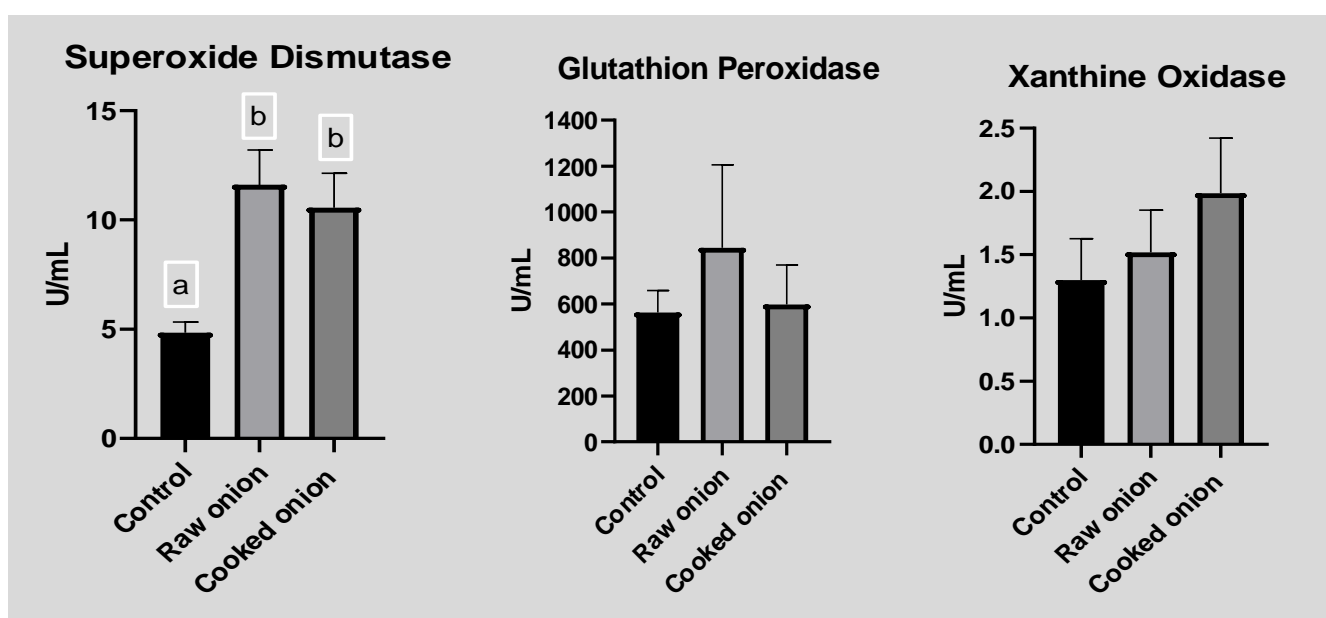


Figure 1 - Effect of raw and cooked onion on the antioxidant enzymes activity in serum of rabbits (mean ± standard error), P<0.05

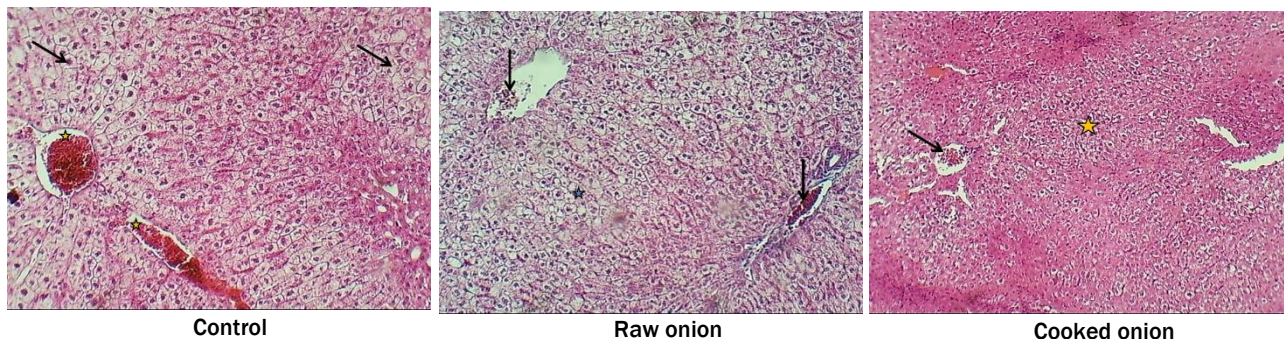


Figure 2 - Photomicrograph of liver from rabbits stained with HandE (x100) (arrows and star)

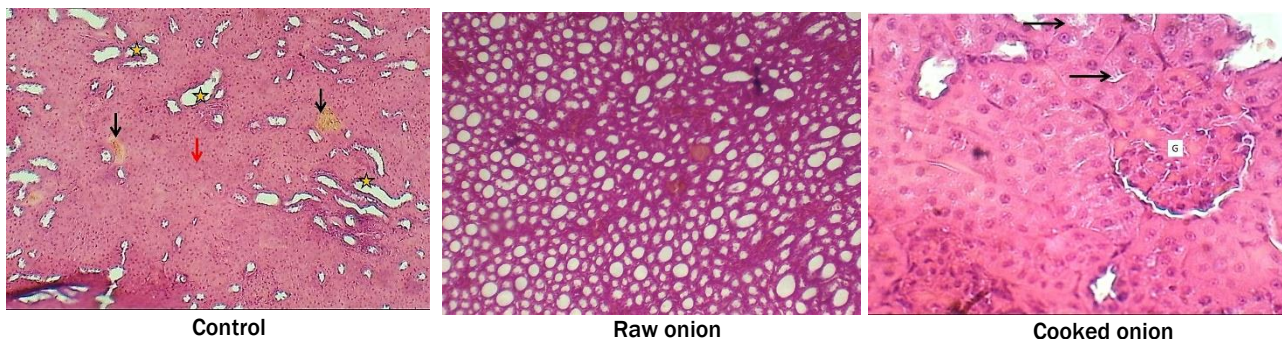


Figure 3 - Photomicrograph of kidney from rabbits stained with HandE (x100) (arrows)

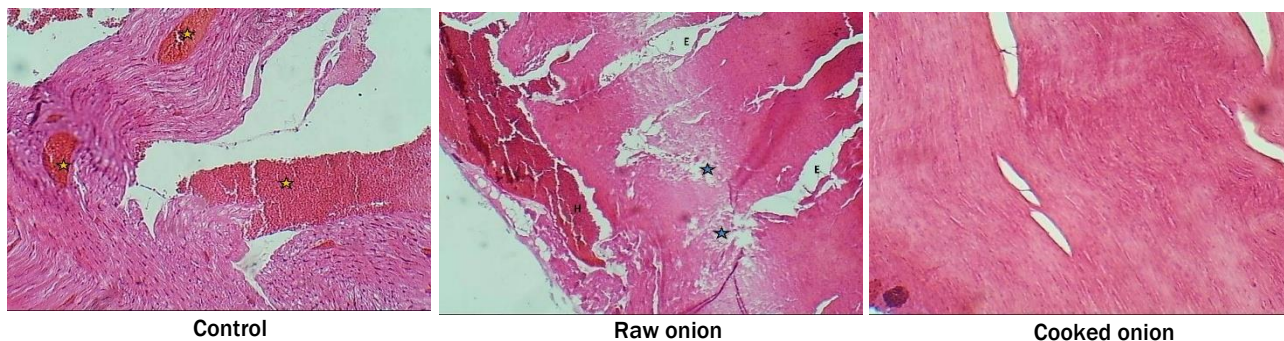


Figure 4 - Photomicrograph of heart from rabbits stained with HandE (x100) (stars)

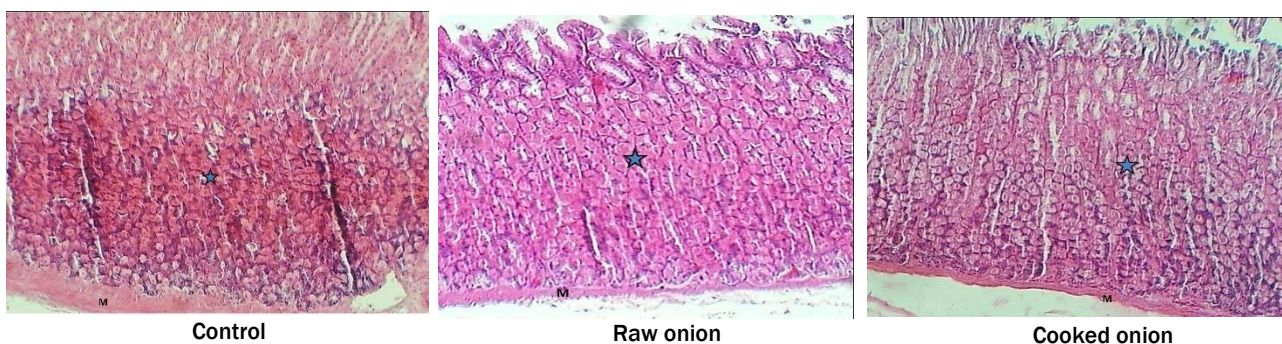


Figure 5 - Photomicrograph of gastric mucosa from rabbits stained with HandE (x100) (stars)

DISCUSSION

In this study, the addition of raw or cooked onions had a limited impact on whole blood characteristics, as decrease in the rate of corpuscular hemoglobin (MCH) and erythrocytes (RBC). This comes in agreement with (Ajao and Ola, 2022) findings. Additionally, these findings supported those of Zewei et al (2016), who discovered no impact of adding raw onions to the diet of rabbits on whole blood characteristics. While they found that adding raw onions to rabbit ration at (400 and 800 mg/kg) significantly reduced the level of total fats, triglycerides, total cholesterol and low density

lipoproteins. These findings conflicted with those of the current investigation, in which we discovered that adding onions, both cooked and raw, had no influence on the lipid index.

The liver, kidneys, and heart tissues were affected, particularly in the rabbits in the control group. This damage may be the result of the feed's lipids being held at high temperatures, which can lead to oxidation and the formation of free radicals (Lin et al., 1998). Additionally, unsanitary feed storage conditions promote the growth of mold, which results in mycotoxins being produced in the fodder (Alam et al., 2014). Free radicals in the body start protein and lipid breakdown, which changes cell permeability and affects the movement of enzymes between cells and serum (Nakamura et al, 1985).

Flavonoids are the main phenols in onions, which can be classified into their sub-families (flavones, flavanones, flavonols, isoflavones, flavanonols, flavanols, chalcones, and anthocyanins), and the most abundant in onions are flavonols (Liguori et al., 2017). Razavi and Kenari (2016) believe that there is an association between the antioxidant activity and free radical elimination of onions' phenolic content. By increasing the concentration of total phenols, the ability of the total phenols extracted from onions to remove free radicals (DPPH, FRAP, and OH) *in vitro* was further enhanced.

Protection of tissues depends on cellular protein synthesis and then entire proper cell performance, which necessarily depends on contribution of antioxidant system. Therefore, several factors may have contributed to maintaining the normal tissue of the kidney and liver without any focal lesions in the rabbits exposed to the two groups of onions, especially the cooked onion group and to a lesser extent in the raw onion group (Ahmed et al., 2017). These factors mainly arose from; role of complete phenols by inhibiting Xanthine oxidase activity (Ouyang et al., 2018), free radical chain reaction stopping by the phenolic OH groups that behave as hydrogen or electron donors (Ahmed et al, 2017), and phenols effective function in reducing malondialdehyde oxidation role.

This study is unique in that it focuses on releasing phenolic compounds, which lose a lot of their active components when plants are cooked, particularly onions, where many studies have shown that cooking has a significant impact on adjusting the content of phenolic compounds in onions (Cattivelli et al, 2021). Some substances, including anthocyanins, may disintegrate at high temperatures or be released into the medium as flavonols after boiling (Palermo et al, 2014). According to results reported by Pellegrini et al. (2009), the release of antioxidant compounds from onion briquettes after they were softened by high heat, the creation of new antioxidant compounds, or polyphenol oxidation to intermediate oxidation states showing higher efficiency in free radical removal were all possible explanations for the increase in total antioxidant capacity of cooked onions. Price et al. (1997) stated that onions that have been fried for five minutes have more quercetin than those that have not. Another study of Lombard et al. (2005) found that baking or frying onions boosts their flavonol concentration and that the cooking duration should not be less than five minutes validated this.

According to the results of the current study, both raw and cooked onions boosted the activity of some antioxidant enzymes, and cooked onions were more effective than raw onions at protecting liver, kidney, and heart tissues against cell necrosis caused by oxidative processes.

Onions are abundant in phenolic compounds, which act as antioxidants. It can be concluded that onions require heat treatment through cooking in order to achieve the greatest benefits from phenolic chemicals. Boiling onions have a protective effect on the liver, kidneys, and cardiac tissues because they protect them from free radicals and other oxidative agents. Increasing the activity of superoxide dismutase is one of those mechanisms.

DECLARATIONS

Corresponding author

Ammar Abdulrazzaq Tawfeeq; E-mail: ammarabta@uoanbar.edu.iq

Authors' contribution

A.A. Tawfeeq was carrying out the experiment of rabbits rearing, and all the other practical parts of the study as well as discussion of results. E.N. Shallal did histological analysis and interpretation. A.M. Abdulwahid examined blood parameters. B.J.M. Aldahham was the owner of the research idea.

Funding

This research received no grant from any funding agency/sector.

Competing interests

The authors declared that there is no any competing interest.

REFERENCES

- Ahmed AF, Al-Yousef HM, Al-Qahtani JH and Al-Said MS (2017). A hepatonephro-protective phenolic-rich extract from red onion (*Allium cepa* L.) peels. *Pakistan Journal of Pharmaceutical Sciences*, 30(5): 1971-1979. <https://www.pjps.pk/wp-content/uploads/pdfs/30/5/Supplementary/9-SUP-720.pdf>
- Ajao BH and Ola SI (2022). Effects of dietary supplementation of ginger, garlic and onion on semen profile, haematological and serum antioxidant status of rabbit bucks raised in the dry season of the humid tropic. *Journal of Agricultural Sciences-Sri Lanka*, 17(1): 228-240. <http://doi.org/10.4038/jas.v17i1.9622>
- Alam S, Shah HU, Afzal M and Magan N (2014). Influence of calcium propionate, water activity and storage time on mold incidence and aflatoxins production in broiler starter feed. *Animal Feed Science and Technology*, 188: 137-144. <https://doi.org/10.1016/j.anifeedsci.2013.11.010>

- Allain CC, Poon LS, Chan CS, Richmond WFPC and Fu PC (1974). Enzymatic determination of total serum cholesterol. *Clinical chemistry*, 20(4): 470-475. <https://doi.org/10.1093/clinchem/20.4.470>
- Alpsoy S, Aktas C, Uygur R, Topcu B, Kanter M, Erboğa M, et al (2013). Antioxidant and anti-apoptotic effects of onion (*Allium cepa*) extract on doxorubicin-induced cardiotoxicity in rats. *Journal of Applied Toxicology*, 33(3): 202-208. <https://doi.org/10.1002/jat.1738>
- Bystrická J, Musilová J, Vollmannová A, Timoracká M, Kavalcová P (2013). Bioactive components of onion (*Allium cepa* L.)—A Review. *Acta Alimentaria*, 42(1): 11-22. <https://doi.org/10.1556/aalim.42.2013.1.2>
- Cattivelli A, Conte A, Martini S and Tagliacucchi D (2021). Influence of cooking methods on onion phenolic compounds bioaccessibility. *Foods*, 10(5): 1023. <https://doi.org/10.3390/foods10051023>
- Cattivelli A, Conte A, Martini S and Tagliacucchi D (2022). Cooking and In Vitro Digestion Modulate the Anti-Diabetic Properties of Red-Skinned Onion and Dark Purple Eggplant Phenolic Compounds. *Foods*, 11(5): 689. <https://doi.org/10.3390/foods11050689>
- Duncan DB (1955). Multiple range and multiple F tests. *Biometrics*, 11(1): 1-42. <https://doi.org/10.2307/3001478>
- Gazuwa SY, Makanjuola ER, Jaryum KH, Kutshik JR and Mafulul SG (2013). The Phytochemical Composition of *Allium Cepa/Allium Sativum* and the Effects of Their Aqueous Extracts (Cooked and Raw Forms) on the Lipid Profile and other Hepatic Biochemical Parameters in Female Albino Wistar Rats. *Asian J. Exp. Biol. Sci.* 4(3):406-410. <https://irepos.unijos.edu.ng/jspui/bitstream/123456789/240/1/Phytochemical%20Composition.pdf>
- Kumar M, Barbhai MD, Hasan M, Punia S, Dhumal S, Rais N, Chandran D, Pandiselvam R, Kothakota A, Tomar M, Satankar V, Senapathy M, Anitha T, Dey A, Sayed AAS, Gadallah FM, Amarowicz R and Mekhemar M (2022). Onion (*Allium cepa* L.) peels: A review on bioactive compounds and biomedical activities. *Biomedicine and Pharmacotherapy*, 146, 112498. <https://doi.org/10.1016/j.biopha.2021.112498>
- Lee B, Jung JH and Kim HS (2012). Assessment of red onion on antioxidant activity in rat. *Food and chemical toxicology*, 50(11), 3912-3919. <https://doi.org/10.1016/j.fct.2012.08.004>
- Liguori L, Califano R, Albanese D, Raimo F, Crescitelli A and Di Matteo M (2017). Chemical composition and antioxidant properties of five white onion (*Allium cepa* L.) landraces. *Journal of Food Quality*, 2017. <https://doi.org/10.1155/2017/6873651>
- Lin S, Hsieh F and Huff HE (1998). Effects of lipids and processing conditions on lipid oxidation of extruded dry pet food during storage. *Animal feed science and Technology*, 71(3-4), 283-294. [https://doi.org/10.1016/S0377-8401\(97\)00157-0](https://doi.org/10.1016/S0377-8401(97)00157-0)
- Lombard K, Peffley E, Geoffriaou E, Thompson L and Herring A (2005). Quercetin in onion (*Allium cepa* L.) after heat-treatment simulating home preparation. *Journal of Food Composition and Analysis*, 18(6): 571-581. <https://doi.org/10.1016/j.jfca.2004.03.027>
- Luna LG 1968. Manual of histology staining methods of the armed forces institute of pathology. 3rd Ed. New York, McGraw-Hill book Com. Pp 38-76 and 222-223. [Google Scholar](https://scholar.google.com/)
- Marefati N, Ghorani V, Shakeri F, Boskabady M, Kianian F, Rezaee R and Boskabady MH (2021). A review of anti-inflammatory, antioxidant, and immunomodulatory effects of *Allium cepa* and its main constituents. *Pharmaceutical biology*, 59(1): 285-300. <https://doi.org/10.1080/13880209.2021.1874028>
- Nakamura T, Fujii T and Ichihara A (1985). Enzyme leakage due to change of membrane permeability of primary cultured rat hepatocytes treated with various hepatotoxins and its prevention by glycyrrhizin. *Cell biology and toxicology*, 1(4): 285-295. <https://doi.org/10.1007/bf00118193>
- Ogunmodede OS, Saalu LC, Ogunlade B, Akunna GG and Oyewopo AO (2012). An evaluation of the hypoglycemic, antioxidant and hepatoprotective potentials of onion (*Allium cepa* L.) on alloxan-induced diabetic rabbits. *International journal of pharmacology*, 8(1), 21-29. <https://dx.doi.org/10.3923/ijp.2012.21.29>
- Ouyang H, Hou K, Peng W, Liu Z and Deng H (2018). Antioxidant and xanthine oxidase inhibitory activities of total polyphenols from onion. *Saudi Journal of Biological Sciences*, 25(7): 1509-1513. <https://doi.org/10.1016/j.sjbs.2017.08.005>
- Paglia DE and Valentine WN (1967). Studies on the quantitative and qualitative characterization of erythrocyte glutathione peroxidase. *The Journal of laboratory and clinical medicine*, 70(1): 158-169. <https://doi.org/10.5555/uri:pii:0022214367900765>
- Palermo M, Pellegrini N and Fogliano V (2014). The effect of cooking on the phytochemical content of vegetables. *Journal of the Science of Food and Agriculture*, 94(6), 1057-1070. <https://doi.org/10.1002/jsfa.6478>
- Paoletti F and Mocali A (1990). [18] Determination of superoxide dismutase activity by purely chemical system based on NAD(P)H Oxidation. *Methods in enzymology* 186: 209-220. [https://doi.org/10.1016/0076-6879\(90\)86110-h](https://doi.org/10.1016/0076-6879(90)86110-h)
- Pellegrini N, Miglio C, Del Rio D, Salvatore S, Serafini M and Brighenti F (2009). Effect of domestic cooking methods on the total antioxidant capacity of vegetables. *International Journal of Food Sciences and Nutrition*, 60(sup2): 12-22. <https://doi.org/10.1080/09637480802175212>
- Price KR, Bacon JR and Rhodes MJ (1997). Effect of storage and domestic processing on the content and composition of flavonol glucosides in onion (*Allium cepa*). *Journal of Agricultural and Food Chemistry*, 45(3): 938-942. <https://doi.org/10.1021/jf9605916>
- Razavi R and Kenari RE (2016). Antioxidant activity of red onion (*Allium cepa* L.) peel extract produced by maceration, ultrasonic assisted and supercritical extraction techniques. In 24th Iranian Food Science and Technology Congress. https://www.researchgate.net/publication/309385808_Antioxidant_activity_of_red_onion_Allium_cepa_L_peel_extract_produced_by_maceration_ultrasonic_assisted_and_supercritical_extraction_techniques
- Sabir SA, El-Gindy YM, Morshehy SA, Zahran SM, Ahmed MH, and Zewail, SH (2019). Semen quality, sex hormone and antioxidant status of male rabbits as influenced by two forms of onion. *Egyptian Poultry Science Journal*, 39(1): 31-39. <https://dx.doi.org/10.21608/epsj.2019.28788>
- Sagar NA, Pareek S, Benkeblia N and Xiao J (2022). Onion (*Allium cepa* L.) bioactives: Chemistry, pharmacotherapeutic functions, and industrial applications. *Food Frontiers*. 2022, 1-33. <https://doi.org/10.1002/fft.135>
- Sans S, Bobo G, Zudaire L, Lafarga T, Sabaté J, Casals J and Simó J (2019). Nutritional values of raw and cooked 'calçots' (*Allium cepa* L. resprouts), an expanding crop. *Journal of the Science of Food and Agriculture*, 99(11): 4985-4992. <https://doi.org/10.1002/jsfa.9733>
- Stirpe F, Della Corte E and Lorenzoni, E (1969). The regulation of rat liver xanthine oxidase: conversion in vitro of the enzyme activity from dehydrogenase (type D) to oxidase (type O). *Journal of Biological Chemistry*, 244(14): 3855-3863. [https://doi.org/10.1016/S0021-9258\(17\)36428-1](https://doi.org/10.1016/S0021-9258(17)36428-1)
- Ülger TG and Çakiroğlu FP (2020). The effects of onion (*Allium cepa* L.) dried by different heat treatments on plasma lipid profile and fasting blood glucose level in diabetic rats. *Avicenna Journal of Phytomedicine*, 10(4): 325-333. <https://doi.org/10.22038/ajp.2019.14066>
- Zweil HS, Ahmed MH, Zahran SM, El-Gindy YM and Al-Ghdaiwi AY (2016). Effects of dried onion and ascorbic acid on performance, immune response and serum blood lipid profiles of growing rabbits. *Journal of the Advances in Agricultural Researches*, 21(4): 571-583. <https://dx.doi.org/10.21608/jalexu.2016.195554>