

AVIAN CELLULITIS: A SKIN AFFECTION ASSOCIATED WITH ECONOMIC LOSSES IN BROILER CHICKENS

Wafaa A. ABD EL-GHANY 

Poultry Diseases Department, Faculty of Veterinary Medicine, Cairo University, Giza, 12211, Egypt

Email: wafaa.soliman@cu.edu.eg

Supporting Information

ABSTRACT: This review was designed for focusing on cellulitis condition in broiler chickens regarding causes, clinical picture, and prevention measures of this condition. Cellulitis is an acute diffuse inflammation of subcutaneous tissues and muscles especially on the skin of thighs and abdomen. This condition is more common in broilers than others and it is usually associated with economic losses. At processing, low grade chicken carcasses and high incidences of condemnation are the sequels of cellulitis. Skin integrity, stocking density, and litter conditions are predisposing factors for induction of cellulitis. However, other infectious bacterial and immunosuppressive viral pathogens are associated with cellulitis. Affected birds display areas of yellow skin along with a plaque of pus underneath the skin and the underlying muscles show hemorrhages. Presence of caseous, yellowish to green, dark red, or brown fetid gangrenous exudate could also be observed in the advanced cellulitis cases. Prevention and control of cellulitis are based on application of hygienic practices, vaccination, antibiotic therapy, genetic selection, and nutrition.

Keywords: Avian cellulitis, Broiler, Disorder, Lesions, Skin.

RESEARCH ARTICLE
 PII: S222877012300006-13
 Received: August 18, 2022
 Revised: January 17, 2023
 Accepted: January 17, 2023

INTRODUCTION

Skin affection is one of the main reasons for broiler carcass condemnation in slaughterhouses (Bergmann et al., 1995). Cellulitis is a skin affection which was described for the first time in Great Britain as necrotic dermatitis, inflammatory process, or infectious process (Randall et al., 1984). Since that time, cellulitis has been established as condemnation category in North America. It can be referred as a consequence of overpopulation and poor flock hygiene rather than a specific disease (Glünder, 1990). From the dermato-pathological point of view, cellulitis can be defined as an acute diffuse and suppurative inflammation of the deep subcutaneous tissues and sometimes the muscles especially on skin of thighs and abdomen (Ghanbarpour et al., 2010). This condition leads to an asymmetrical change of skin texture with uneven discoloration.

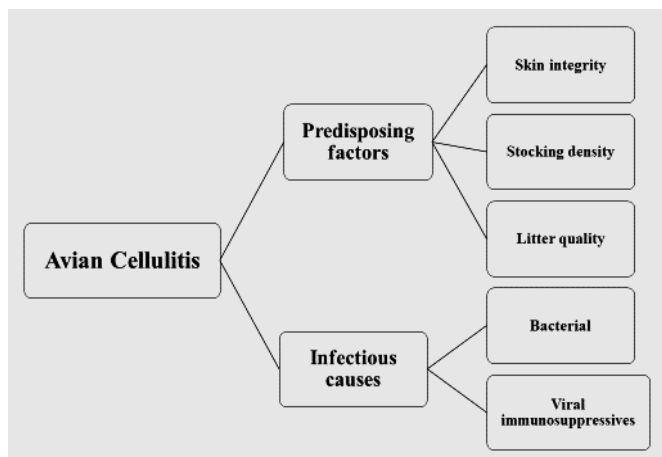
Avian cellulitis is a serious problem that has a great economic influence on broiler production system. Cellulitis induces down grading and carcass condemnation at processing with high labor costs to process affected flocks (Salines et al., 2017; Radwan et al., 2018; Silva et al., 2021; Schulze Bernd et al., 2022). Aguiar et al. (2020) noted that cellulitis is one of the most important causes of carcass rejection in slaughter plants. Low grade and rejected carcasses associated with cellulitis have been estimated to cost \$30 million to \$40 million annually (Norton, 1997). In Germany, the total condemnation ratio was 1.4%, while condemnation due to cellulitis was 0.52%, representing 36.77% of all condemnations (Schulze Bernd et al., 2020).

Skin scratches or abrasions enhances the bacterial colonization of subcutaneous tissues (Norton et al., 1999), resulting in typical cellulitis lesions (Jeffrey et al., 2004). Other predisposing factors including inadequate management and nutrition, cannibalism, biting insects, bad litter quality, bad ventilation, high stocking density, and poor feed quality may induce cellulitis (Schrader et al., 2004).

Accordingly, this review article was designed for focusing on cellulitis regarding the causes, clinical picture, and prevention and control measures in broiler chickens.

Causes

The possible causes of avian cellulitis is represented in Figure 1.



Predisposing non-infectious factors

Scratched, injured, or traumatized skin is an important predisposing factor for cellulitis induced by *Escherichia coli* (*E. coli*) (Macklin et al., 1999). The alkaline pH of the skin surface and fragility of the dermal layer produced loose extracellular matrix components. Outbreaks of cellulitis are common in broiler flocks with high stocking density. Rising of the flock density is more likely to result in increasing of birds' nervousness, cannibalism, skin injuries and subsequently entrance of organisms to induce cellulitis (Glünder, 1990). Bird's abdomens are the most contact areas to wet or caked litter, therefore, skin abrasions and the possibility of cellulitis are common in these sites (Marrow, 2008). Besides, wet litter may lead to heavy dirty contaminated nails and consequently increasing the susceptibility to skin abrasions.

Immunosuppressive viruses

Presence of immunosuppressive viral diseases increasing the susceptibility to cellulitis in chickens. Alves et al. (2007) pointed out that cellulitis had been observed in infectious bursal disease virus (IBDV) infected broilers which appeared as yellowish plaques under the skin and subcutaneous tissues. The early study of Rosenberger et al. (1975) revealed that gangrenous dermatitis could be detected following early infection with IBDV and adenoviruses in hemorrhagic-aplastic-anemia syndrome affected broilers. However, cases of staphylococcal gangrenous dermatitis were observed in 17-day-old broiler chicks secondary to IBDV infection (Cervantes et al., 1988).

Bacterial infections

Cellulitis is a necrotizing soft-tissue infection caused by a single microbial or a mixture of aerobic and anaerobic bacteria that act synergistically (Gunderson, 2011).

Escherichia coli

During the past 15 years, the condemnation rates due coliform cellulitis has been increased (Umar et al., 2015). *E. coli* is regarded as the predominant pathogen isolated from cellulitis lesions (Silva et al., 2021) as it has been usually associated with litter contamination (Schrader et al., 2004). Clinical signs of cellulitis are probably observed in case of minimum infection pressure of avian pathogenic *E. coli* (APEC) and possibly also seen with other predisposing factors in the flocks (Barbieri et al., 2013). Moreover, strains of *E. coli* which isolated from cellulitis lesions may produce cytotoxins, causing intense cytoplasmic vacuolization of cells and termed as *E. coli* vacuolating factor (Quel, 2013). About 91.8% of cellulitis cases were associated with APEC infection, while the remainder cases of broiler chickens showed mixed infection with *S. aureus* and other bacteria (Derakhshanfar and Ghanbarpour, 2002). de Brito et al. (2002) isolated *E. coli* from broiler chickens with cervical cellulitis, while de Brito et al. (2003) detected strains of *E. coli* originating from cellulitis lesions in 52 batches of broilers from the southern states of Brazil. In the study of Barros et al. (2013), the results indicated isolation of *E. coli* in 82.5% of cases with cellulitis.

Despite it is not clear which are the specific serotypes of *E. coli* can cause cellulitis in broilers (Jeffrey et al., 2004), *E. coli* induced cellulitis in broilers share a close genetic relationship (Poulsen et al., 2018). Several different of *E. coli* were serogrouped from cellulitis cases, serogroups O78, O1, and O2 were prevalent ones (Fard et al., 2007). An early study of Ngeleka et al. (1996) revealed isolation of 39 *E. coli* associated cellulitis isolates and 38.4% of the isolates were serogroups O25 and O78. Radwan et al. (2018) demonstrated that *E. coli* serogroups recovered from cellulitis lesions were O125; 32%, followed by O158, O55, and O78 as 24%, 12%, and 1%, respectively, then both O1 and O8; 6% for each, and finally O15; 4%. However, large groups of non-serotyped *E. coli* have been also isolated from cellulitis lesions (Macklin et al., 1999). Asadi et al. (2018) demonstrated 34 *E. coli* isolates from broiler carcasses with cellulitis during processing which were belonged to phylogroups; A (55.88%), B1 (5.88%), and D (38.24%).

Staphylococci species

Cases of vesicular dermatitis in chickens have been early reported due to *Staphylococcus epidermidis* (*S. epidermidis*) (Shimizu et al., 1967). However, *S. aureus* was frequently isolated from broiler chicken carcasses with cellulitis (Derakhshanfar and Ghanbarpour, 2002). Radwan et al. (2018) demonstrated that out of 157 bacterial isolates, 8 isolates of *S. aureus* (5.1%) were found in the muscles, liver and heart blood of broilers with cellulitis.

Proteus species

Proteus species were isolated from turkeys had cellulitis in slaughter houses (Olkowski et al., 1999). In the study of Radwan et al. (2018), 9 out of 157 bacterial isolates (5.7%) were identified as *Proteus* species from cellulitis. *Proteus vulgaris* (*P. vulgaris*) was identified in the subcutaneous tissues of cellulitis lesions (Gomis et al., 2002), while *P. mirabilis* was found in 40% of chickens with swollen head (Shawki et al., 2017; Sanches et al., 2020).

Other bacterial species

It has been documented that *Aeromonas* species can colonize the subcutaneous tissues of broiler chickens with cellulitis (Gomis et al., 2002), as well as turkey carcasses in slaughter houses (Olkowski et al., 1999). *Pseudomonas* species were detected in turkey carcasses with cellulitis lesions during processing (Olkowski et al., 1999), particularly, *Pseudomonas aeruginosa* (*P. aeruginosa*) (Gomis et al., 2002). Besides, Shawki et al. (2017) isolated *P. aeruginosa* from 25% of chickens with swollen head syndrome. A mixture of *Clostridium colinum* (*C. colinum*), *C. septicum*, *C. perfringens*, and *C. sordelli* could induce cellulitis (Umar et al., 2015). For the first time, *Salmonella kossen* was isolated from broiler chickens with cellulitis in Egypt (Radwan et al., 2018). *Streptococcus dysagalactae* was also identified from broilers

chicken carcasses (Vaillancourt et al., 1992). Other bacteria such as, *Pasteurella multocida*, *Enterobacter agglomerans*, *Citrobacter ferundi*, and *Aerobacter* were isolated from cases of cellulitis (Radwan et al., 2018). Some bacteria with public health importance such as *Trueperella* (formerly *Actinomyces*) *pyogenes* and *Erysipelothrix rhusiopathiae* were incriminated as the causes of cellulitis (Derakhshanfar et al., 2004).

Clinical picture

The severity of cellulitis condition is related to some factors such as genetic condition, breed, sex, chick quality, immune status, and skin integrity of the affected bird, the surrounding environment and management conditions, and the feeding quantity and quality (Fard et al., 2007). Affected birds usually do not show any signs, however the lesions are only detected at the slaughterhouses. Usually cellulitis lesions are in apparent and difficult to be detected in the affected birds due to covering of the lesions with feathers (Gomis et al., 2001). The clinical picture of cellulitis could be observed if the infection occurs in the head region as swollen head (Morley and Thomson, 1984). The mortality rate has been recorded especially in cases with septicemia (Ghanbarpour et al., 2003).

Cellulitis could be observed as yellow and thickened skin over the lower abdomen and thigh along with spreading of edematous plaques of pus in the deep subcutaneous tissue, and the underlying muscles may display hemorrhages. Caseated sheets of fibrinous exudates adjacent to the lower abdomen and thigh may be also observed. The severity and the size of the lesions vary from one bird to another, some show localized and well-demarcated pea-size lesions, while others exhibit an extensive purulent inflammation covering most of the abdomen and breast muscles.

Oozing of exudate over the skin “waffle or honeycombed skin” could be also observed over the thigh and muscles, legs, abdomen, head, neck, back, and cloacal area (Alves et al., 2007). Deskinning showed presence of the characteristic plaques, ‘flakes’ or caseous, yellowish to green, dark red, or brown exudate that it can be fetid if gangrenous (Bianco et al., 2016).

Affected birds with cellulitis may occasionally show concurrent lesions of systemic affections, suggesting that cellulitis may result from systemic spread or, equally, the localized skin lesions may be a source for systemic disease. After experimental cellulitis, the lesions could appear away from the inoculation site that migrated from the dorsal to the abdominal area (Norton, 1997). Silva et al. (2021) demonstrated the relationship between *E. coli* in cellulitis of broiler chickens and the liver lesions as well as the possible systemic infection. Hepatitis, airsacculitis, and pericarditis were frequently associated lesions with cellulitis (Gomis et al., 2001; Silva et al., 2021). Cellulitis-struck broilers may have also lesions in the heart, bones, and joints (Gomis et al., 2001).

Subcutaneous inoculation of 25-day-old broiler chickens with *E. coli* serogroup O78 induced cellulitis lesions in 98% of the inoculated birds and the pathogen was isolated from more than 75% of cellulitis lesions (Gomis et al., 2001). Johnson et al. (2001) experimentally inoculated *E. coli* in broilers to enhance the induction of cellulitis lesions and to detect the other clinical picture of colibacillosis, particularly perihepatitis, pericarditis, and airsacculitis. Moreover, cellulitis and myositis lesions were developed in cage-reared broilers after infection with a mixture of *C. perfringens*, *C. septicum*, and *S. aureus*, following vaccination with IBDV and chicken anaemia virus (CAV) vaccines (Wang et al., 2005).

Microscopically, hyperkeratosis, thickening of the dermis, infiltration of mononuclear cells and heterophils along with fibrinocaseous exudates were associated with cellulitis (Vieira et al., 2006). Moreover, Bianco et al. (2016) defined cellulitis as severe, subacute to chronic, focal to locally extensive fibrinoheterophilic, granulomatous to necrotizing cellulitis, panniculitis, dermatitis, and myositis with irregular hyperkeratosis.

Prevention and control

Cellulitis must be approached as a multi factorial problem as which there is no one solution, therefore it must be multi-levels to deal with the problem. There is no specific preventive measures or available vaccines against cellulites, therefore, reducing the incidence of skin injuries can reduce the incidence rate at processing. Adoption of appropriate farm-specific cloths, changing of shoes, and an adequate cleaning of the broiler houses after each grow out period could improve outcomes regarding condemnation ratios due to cellulitis (Schulze Bernd et al., 2022). Avoid hot environment especially between 2 to 4 weeks of age to stimulate the feathers growth and consequently minimize cellulitis occurrence. Reducing stocking density and overcrowding can reduce the possibility of skin abrasions or bruising and subsequently cellulitis. Increasing drinkers and feeders to reduce the possibility of fighting and skin wounds. Removal of wet litter and replace it by clean and dry one is important. Decreasing slaughtering age and improving the welfare and management policies of poultry flocks can lead to less carcass condemnations due to cellulitis (Fard et al., 2007).

Introduction of genetic lines with a slow growth of feather increases the occurrence of cellulitis. Modern broilers breeds have large chest and abdomen that exposing them to more skin injuries. Therefore, supporting the feathers growth and selection of genetic lines of broilers with a rapid growth of feathers are important to reduce cellulitis.

Regular adoption of vaccination protocols against some viral diseases such as IBDV and CAV may reduce the incidence of cellulitis. Early protection from IBDV can help in the prevention of staphylococcosis (Santivatr et al., 1981). Moreover, trials to produce autogenous vaccines against APEC can help in reducing the incidence of *E. coli* associated cellulites. Treatment with a specific antimicrobials is one of the primary control measures for reducing cellulitis caused by APEC and other bacterial infections. Supplementation with nutrient substances such as vitamin E, zinc, copper, selenium, and manganese can improve the feather development (Macklin et al., 2000). Moreover, the incidence of cellulitis and the

carcass condemnation rate were significantly reduced in broiler chickens treated with *Bifidobacterium bifidum* (Estrada et al., 2001).

CONCLUSION

Cellulitis represents a serious problem for broilers industry causing great financial losses as a result of low grade chicken carcasses and high incidences of condemnation at processing. Prevention of such condition are difficult due to the multifactorial non-infectious and infectious causes. Bad management practices associated with infectious pathogens increase the incidence of cellulitis. Accordingly, prevention of predisposing management factors through adoption of biosecurity measures is critical. Moreover, treatment of suspected bacterial causes of cellulitis may reduce the severity of this condition.

DECLARATIONS

Corresponding author

E-mail: wafaa.soliman@cu.edu.eg

Author's contribution

Abd El-Ghany WA has collected and drafted the manuscript, formatted it, and approved the final manuscript.

Conflict of interests

The author has not declared any conflict of interest.

REFERENCES

- Aguiar JF, Silva WC, and Camargo Junior RNC (2020). Celulite em frangos de corte por *Escherichia coli*. Veterinária e Zootecnia, 27: 1-11. DOI: <https://doi.org/10.35172/rvz.2020.v27.468>
- Alves FM, Pereira VL, Nascimento ER, Guimarães AM, Almeida DO, and Tortelly R (2007). Cellulitis associated with lesions of bursa of Fabricius from broilers under sanitary inspection. Revista Brasileira de Ciência Veterinária, 14(1): 23-27. Available at: <https://www.bvs-vet.org.br/vetindex/periodicos/revista-brasileira-de-ciencia->
- Asadi A, Salehi TZ, Jamshidian M, and Ghanbarpour R (2018). ECOR phylotyping and determination of virulence genes in *Escherichia coli* isolates from pathological conditions of broiler chickens in poultry slaughterhouses of southeast of Iran. Veterinary Research Forum, 9(3): 211-216. DOI: <https://doi.org/10.30466/vrf.2018.30827>
- Barbieri NL, de Oliveira AL, Tejkowski TM, Pavanelo DB, Rocha DA, Matter LB, et al. (2013). Genotypes and pathogenicity of cellulitis isolates reveal traits that modulate APEC virulence. PLoS One, 8(8): e72322. DOI: <https://doi.org/10.1371/journal.pone.0072322>
- Barros LSS, Silva RM, Silva IM, Baliza MD, and Virgílio FF (2013). *Escherichia coli* from cellulitis lesions in broilers. Journal of Food Measurement and Characterization, 7(1): 40-45. DOI: <https://doi.org/10.1007/s11694-013-9138-3>
- Bergmann V, Koglin K, and Valentin A (1995). Skin diseases as a reason for condemnation of broiler carcasses. Tierärztliche Praxis, 23(4), 374-380. Available at: <https://pubmed.ncbi.nlm.nih.gov/8578570/>
- Bianco C, Balanescu B, Cieslicka U, Balanescu P, Stefanov K, Lopez P, et al. (2016). The shades of avian cellulitis in meat-type chicken. Research & Reviews: Journal of Veterinary Sciences, 2(2): 49-52. Available at: <https://www.roj.com/open-access/the->
- Cervantes H, Munger L, Ley D, and Ficken M (1988). *Staphylococcus*-induced gangrenous dermatitis in broilers. Avian Diseases, 32(1): 140-142. DOI: <https://doi.org/10.2307/1590963>
- de Brito BG, Tamehiro CY, Okano W, Luzardo MM, Berbel MM, and Guimarães LG (2002). Cervical cellulitis in broiler chickens for *Escherichia coli*. Semina: Ciências Agrárias, 23(1): 81-84. DOI: <https://doi.org/10.5433/1679-0359.2002v23n1p81>
- de Brito BG, Gaziri LC, and Vidotto MC (2003). Virulence factors and clonal relationships among *Escherichia coli* strains isolated from broiler chickens with cellulitis. Infection and Immunity, 71(7): 4175-4177. DOI: <https://doi.org/10.1128/iai.71.7.4175-4177.2003>
- Derakhshanfar A, and Ghanbarpour R (2002). A study on avian cellulitis in broiler chickens. Veterinarski Arhiv, 72(5): 277-284. Available at: <https://hrcak.srce.hr/file/120625>
- Derakhshanfar A, Ghanbarpour R, and Yazdani S (2004). A pathologic study on experimental *Erysipelothrix rhusiopathiae* cellulitis in broiler chickens. Veterinarski Arhiv, 74(3): 217-224. Available at: <https://hrcak.srce.hr/67883>
- Estrada A, Wilkie DC, and Drew M (2001). Administration of *bifidobacterium bifidum* to chicken broilers reduces the number of carcass condemnations for cellulitis at the abattoir. Journal of Applied Poultry Research, 10(4): 329-334. DOI: <https://doi.org/10.1093/japr/10.4.329>
- Fard B, Karimi MH, Fathi V, and Behmanesh RE (2007). Bacteriologic survey on infectious cellulitis in broiler chickens in Masjid Soleiman slaughterhouse, Iran. Archives of Razi Institute, 62(2): 91-95. DOI: <https://doi.org/10.22092/ari.2007.103773>
- Ghanbarpour R, Derakhshanfar A, and Pournabakhsh A (2003). Determination of P (F11) and F1 fimbriae of *Escherichia coli* isolated from avian cellulitis. Veterinarski Arhiv, 73(4): 227-236. Available at: <https://hrcak.srce.hr/file/110429>
- Ghanbarpour R, Salehi M, and Oswald E (2010). Virulence genotyping of *Escherichia coli* isolates from avian cellulitis in relation to phylogeny. Comparative Clinical Pathology, 19(2): 147-153. DOI: <https://doi.org/10.1007/s00580-009-0837-4>
- Glünder G (1990). Dermatitis in broilers caused by *Escherichia coli*: isolation of *E. coli* from field cases, reproduction of the disease with *E. coli* O78:K80 and conclusions under consideration of predisposing factors. Zentralblatt für Veterinärmedizin B, 37(5): 383-391. DOI: <https://doi.org/10.1111/j.1439-0450.1990.tb01073.x>
- Gomis SM, Riddell C, Potter AA, and Allan BJ (2001). Phenotypic and genotypic characterization of virulence factors of *Escherichia coli* isolated from broiler chickens with simultaneous occurrence of cellulitis and other colibacillosis lesions. Canadian Journal of Veterinary Research, 65(1): 1-6. Available at: <https://pubmed.ncbi.nlm.nih.gov/11227188>

- Gomis S, Amoako AK, Ngeleka AM, Belanger L, Althouse B, Kumor L, et al. (2002). Histopathologic and bacteriologic evaluations of cellulitis detected in legs and caudal abdominal regions of turkeys. *Avian Diseases*, 46(1): 192-197. DOI: [https://doi.org/10.1637/0005-2086\(2002\)046\[0192:habeoc\]2.0.co;2](https://doi.org/10.1637/0005-2086(2002)046[0192:habeoc]2.0.co;2)
- Gunderson CG (2011). Cellulitis: definition, etiology, and clinical features. *The American Journal of Medicine*, 124(12): 1113-1122. DOI: <https://doi.org/10.1016/j.amjmed.2011.06.028>
- Jeffrey JS, Singer RS, O'Connor R, and Atwill ER (2004). Prevalence of pathogenic *Escherichia coli* in the broiler house environment. *Avian Diseases*, 48(1): 189-195. DOI: <https://doi.org/10.1637/7043>
- Johnson LC, Bilgili SF, Hoerr FJ, McMurtrey BL, and Norton RA (2001). The influence of *Escherichia coli* strains from different sources and the age of broiler chickens on the development of cellulitis. *Avian Pathology*, 30(5): 475-478. DOI: <https://doi.org/10.1080/03079450120078662>
- Macklin KS, Norton RA, and McMurtrey BL (1999). Scratches as a component in the pathogenesis of avian cellulitis in broiler chickens exposed to cellulitis origin *Escherichia coli* isolates collected from different regions of the US. *Avian Pathology*, 28(6): 573-578. DOI: <https://doi.org/10.1080/03079459994362>
- Macklin KS, Norton RA, Hess JB, and Bilgili SF (2000). The effect of vitamin E on cellulitis in broiler chickens experiencing scratches in a challenge model. *Avian Diseases*, 44(3): 701-705. DOI: <https://doi.org/10.2307/1593115>
- Marrow C (2008). Cellulitis in management as a cause of disease in poultry. *Poultry Diseases*, Jordan FTW, Pattison M, McMullin P, Bradbury JM, and Alexander D, 6th ed. W B Saunders Ltd., PP. 542.
- Morley AJ, and Thomson DK (1984). Swollen-head syndrome in broiler chickens. *Avian Diseases*, 28(1): 238-243. Available at: <https://pubmed.ncbi.nlm.nih.gov/6326742/#:~:>
- Ngeleka M, Kwaga JK, White DG, Whittam TS, Riddell C, Goodhope R, et al. (1996). *Escherichia coli* cellulitis in broiler chickens: clonal relationships among strains and analysis of virulence-associated factors of isolates from diseased birds. *Infection and Immunology*, 64(8): 3118-3126. DOI: <https://doi.org/10.1128/iai.64.8.3118-3126.1996>
- Norton RA (1997). Avian cellulitis. *World's Poultry Science Journal*, 53(4): 337-349. DOI: <https://doi.org/10.1079/WPS19970027>
- Norton RA, Macklin KS, and McMurtrey BL (1999). Evaluation of scratches as an essential element in the development of avian cellulitis in broiler chickens. *Avian Diseases*, 43(2): 320-325. Available at: <https://pubmed.ncbi.nlm.nih.gov/10396647/>
- Olkowski AA, Kumor L, Johnson D, Bielby M, Chirino Trejo M, and Classen HL (1999). Cellulitis lesions in commercial turkeys identified during processing. *Veterinary Record*, 145(8): 228-229. DOI: <https://doi.org/10.1136/vr.145.8.228>
- Poulsen LL, Bisgaard M, Jørgensen SL, Dideriksen T, Pedersen JR, and Christensen H (2018). Characterization of *Escherichia coli* causing cellulitis in broilers. *Veterinary Microbiology*, 225: 72-78. DOI: <https://doi.org/10.1016/j.vetmic.2018.09.011>
- Quel NG (2013). *Escherichia coli* Vacuolating Factor (ECVF) as a factor associated with avian cellulite. Master's Dissertation, Institute of Biomedical Sciences, São Paulo University, São Paulo. DOI: <https://dx.doi.org/10.11606/D.42.2014.tde-27062014-171721>
- Radwan IA, Abed AH, Abd Allah MM, and Abd El-Latif MAA (2018). Bacterial pathogens associated with cellulitis in chickens. *Journal of Veterinary Medical Research*, 25(1): 68-79. DOI: <https://dx.doi.org/10.21608/jvmr.2018.43303>
- Randall CJ, Meakins PA, Harris MP and Watt DJ (1984). A new skin disease in broilers? *Veterinary Record*, 114(10): 246. DOI: <https://doi.org/10.1136/vr.114.10.246>
- Rosenberger K, Klopp S, Eckroade RJ, and Krauss WC (1975). The role of the infectious bursal agent and several avian adenoviruses in the hemorrhagic-aplastic-anemia syndrome and gangrenous dermatitis. *Avian Diseases*, 19(4): 717-729. Available at: <https://pubmed.ncbi.nlm.nih.gov/173278/>
- Salines M, Allain V, Roul H, Magras C, and Le Bouquin S (2017). Rates of and reasons for condemnation of poultry carcasses: harmonised methodology at the slaughterhouse. *Veterinary Record*, 180(21): 516. DOI: <https://doi.org/10.1136/vr.104000>
- Sanches MS, Baptista AAS, de Souza M, Menck-Costa MF, Justino L, Nishio EK, Oba A, Bracarense APFRL, and Rocha SPD (2020). *Proteus mirabilis* causing cellulitis in broiler chickens. *Brazilian Journal of Microbiology*, 51(3): 1353-1362. DOI: <https://doi.org/10.1007/s42770-020-00240-1>
- Santivatr D, Maheswaran SK, Newman A, and Pomeroy BS (1981). Effect of infectious bursal disease virus infection on the phagocytosis of *Staphylococcus aureus* by mononuclear phagocytic cells of susceptible and resistant strains of chickens. *Avian Diseases*, 25(2): 303-311. DOI: <https://doi.org/10.2307/1589924>
- Schrader JS, Singer RS, and Atwill ER (2004). A prospective study of management and litter variables associated with cellulites in California broiler flocks. *Avian Diseases*, 48(3): 522-530. DOI: <https://doi.org/10.1637/7125>
- Schulze Bernd K, Wilms-Schulze Kump A, Rohn K, Reich F, and Kehrenberg C (2020). Management factors influencing the occurrence of cellulitis in broiler chickens. *Preventive Veterinary Medicine*, 183: 105146. DOI: <https://doi.org/10.1016/j.prevetmed.2020.105146>
- Schulze Bernd K, Wilms-Schulze Kump A, Freise F, Reich F, and Kehrenberg C (2022). Influences of biosecurity on the occurrence of cellulitis in broiler flocks. *Journal of Applied Poultry Research*, 31(1): 100230. DOI: <https://doi.org/10.1016/j.japr.2021.100230>
- Shawki MM, Lebda MA, Shahin AM, and Nassif SA (2017). Some studies on swollen head syndrome in broiler chickens in Egypt. *Zagazig Veterinary Journal*, 45(S1): 132-141. DOI: <https://doi.org/10.21608/zvjz.2019.28658>
- Shimizu T, Horiuchi T, Shoya S, Nomura M, and Shibata S (1967). An outbreak of chicken vesicular dermatitis due to *Staphylococcus epidermidis*. *Bulletin of National Institute of Animal Health*, 55: 21. [Google Scholar](https://scholar.google.com/)
- Silva RM, Silva IMM, Jesus MC, Fernandes MDB, Oliveira FS, and Evêncio-Neto J (2021). Co-relationship between *Escherichia coli* in broiler cellulitis and liver lesions. *Brazilian Journal of Biology*, 81(3): 714-718. DOI: <https://doi.org/10.1590/1519-6984.230243>
- Umar S, Nawaz S, Shahzad M, Munir MT, and Shah MAA (2015). Emerging issue of gangrenous dermatitis in broilers. *Journal of Avian Research*, 1(2): 17-19. Available at: <https://www.researchgate.net/profile/Muhammad-Tanveer>
- Vaillancourt JP, Elfadil A, and Bisailon JR (1992). Cellulitis in the broiler fowl. *Medicine Veterinaire Quebec*, 22: 168-172. Available at: [CAB DIRECT](https://pubmed.ncbi.nlm.nih.gov/10396647/)
- Vieira TB, Franco RM., Magalhães H, Praxedes CS, and Tortelly R (2006). Cellulitis in broilers slaughtered under sanitary inspection: gross and histopathological lesions associated with isolation of *Escherichia coli*. *Revista Brasileira de Ciência Veterinária*, 13(3): 174-177. DOI: <http://dx.doi.org/10.4322/rbcv.2014.388>
- Wang C, Macklin KS, Krehling JT, and Norton RA (2005). Influence of infectious bursal disease and chicken anemia vaccines on the development of cellulitis and myositis lesions in cage-reared broilers. *Journal of Applied Animal Research*, 27(2): 65-69. DOI: <https://doi.org/10.1080/09712119.2005.9706542>