



Immunoreactivities to α -SMA and S-100 Proteins in the Testis of the African Four-toed Hedgehog (*Atelerix albiventris*)

Samuel Gbadebo Olukole^{1*}, Oluwakayode Michael Coker² and Bankole Olusiji Oke¹

¹Department of Veterinary Anatomy, Faculty of Veterinary Medicine, University of Ibadan, Nigeria.

²Department of Wildlife and Ecotourism Management, Faculty of Renewable Natural Resources, University of Ibadan, Nigeria.

*Corresponding author's Email: deborolukole@yahoo.com; ORCID: 0000-0003-2260-3286

ABSTRACT

The African four-toed hedgehog is a small nocturnal mammal, characterized by a short-grooved brown or grey spine covering the dorsum of the body with a band of whitish fur running across their forehead, little is known about the reproductive biology of this animal. The present study aimed to evaluate the validity of immunohistochemistry in the differential labelling of the different cellular components of the testis of the African four-toed hedgehog. Paraffin-embedded testicular sections were stained by conventional histological technique using ten male African four-toed hedgehogs captured from the wild animals in Ibadan, Nigeria. Primary antibodies against alpha smooth muscle actin (α -SMA) and S-100 were applied on paraffin sections. The peritubular myoid cells, the testicular capsule and vascular endothelium expressed strong immunostaining for α -SMA. The spermatogenic cells, Sertoli and Leydig cells, peritubular myoid cells, the testicular capsule, straight tubules as well as rete testis and vascular endothelium all expressed positive immunostaining for S-100. α -SMA and S-100 proteins play active roles in cytoskeletal physiology of testis of the African four-toed hedgehog while S-100 protein plays additional role in the structural formation and maintenance of the blood-testis barrier during the process of spermatogenesis in the animal. It is concluded that α -SMA and S-100 proteins has active roles in the cytoskeletal structure of testis and physiology of the African four-toed hedgehogs.

Keywords: African four-toed hedgehog, Immunoreactivities, Spermatogenic cells, Sertoli cells, Testis.

INTRODUCTION

The order insectivore comprises several families that include shrews, moles, hedgehogs, solenodons, tenrecs and golden moles (Bedford et al., 2000). The African four-toed hedgehog (*Atelerix albiventris*), family *Erinaceidae*, widespread in West Africa, is an inhabitant of plains, savannas, and grassland (Kingdon, 1997). It has been described as a small nocturnal mammal, characterized by a short-grooved brown or grey spine covering the dorsum of the body with a band of whitish fur running across their forehead. The fifth toe on the hind feet, which is present in other species of Hedgehogs is reduced to vestigial hallux in this animal, hence the name "four-toed" and there is no sexual dimorphism (Reeve, 1994; Coker et al., 2018).

Despite its exploitation as a popular pet in the United States (Mori and O'Brien, 1997) as well as its use in biomedical research, the animal is listed as least concern in the IUCN red list category in view of its wide distribution and high tolerance to a degree of habitat modification (Cassola, 2016). It has been reported that *Atelerix albiventris* reaches sexual maturity in the wild at about 1-year of age but sexual maturity may be attained at 2-4 months (Smith, 1992; Symonds, 1999). Nevertheless, there is no record of its successful captive - breeding thus far (Santana et al., 2010).

Previous reports on the African four-toed hedgehog have focused on reproductive characteristics (Smith, 1992; Symonds, 1999; Bedford et al., 2000); skull morphometry (Couture et al., 2015; Girgiri et al., 2015); disease occurrence in captive animals (Gardhouse and Eshar, 2015) and appendicular skeleton morphology (Girgiri et al., 2016). Thus, there is paucity of research information on the reproductive biology of the African four-toed hedgehog (Olukole et al., 2020). In particular, nothing, to our knowledge, has been reported on the presence, localisation and activities of proteins in the testis of this animal.

This study was therefore aimed to investigate the immunohistochemical localization of alpha smooth muscle actin (α -SMA) and S-100 proteins in the testis of the African four-toed hedgehog as contribution to existing literature and possible improvement in the understanding of the testicular architecture and function and the captive-breeding programmes of this animal.

MATERIALS AND METHODS

Animals and tissues

Ten male African four-toed hedgehog, captured from the wild in Ibadan, Oyo State, Nigeria, between the months of May and October (wet season), 2016 were used for the study. The male hedgehogs had an externally visible penis, located in the mid-abdomen, but the testicles were recessed into pouches close to the anus ([World Heritage Encyclopedia, 2017](#)). Hedgehogs were anaesthetised with a subcutaneous injection of 20 mg/kg ketamine in the area of the back ([Henke et al., 2007](#)), sacrificed and the testis was retrieved immediately and fixed in buffered neutral formalin.

Ethical approval

Experiments were carried out according to the guidelines and approval of the institutional ethical committee of the University of Ibadan, Nigeria (UIACUREC: 12/17/05).

Histology and immunohistochemistry

Samples of the testes were fixed in Bouin's fluid and embedded in paraffin blocks. Sections 2-4 μm thick were stained with Haematoxylin and Eosin ([Alkafafy et al., 2012](#)). The slides were then studied under a light microscope (Olympus BX63, Germany, with DP72 camera). Immunohistochemistry was carried out as reported by [Aire and Ozegebe \(2007\)](#). Briefly, paraffin-embedded tissues of testis were cut and mounted on slides pre-coated with polylysine. They were deparaffinised, rehydrated and heat-treated for antigen retrieval. To reduce endogenous peroxidase activity, sections were incubated for 5 min in hydrogen peroxide (3% in distilled water). In order to block non-specific binding sites, the slides were rinsed in a 0.01 M phosphate buffered saline solution (PBS, pH: 7.4), containing bovine serum albumen, for 5 minutes. Prior to immunostaining, validation trials for each of S-100 and α -smooth muscle actin antibodies in this species were carried out using four different dilutions (1: 50, 1: 100, 1:200 and 1:400). Immunostaining of slides were carried out for one hour at room temperature, using the LSAB-plus kit (Dakocytomation, Glostrup Co, Denmark) monoclonal antibodies against S-100 and α -smooth muscle actin at dilutions of 1:100 and 1:400, respectively. The slides were then rinsed in PBS followed by incubation for 15 minutes in a link antibody (Biotinylated secondary antibody, LSAB-plus kit; Dakocytomation) and then in peroxidase-labelled streptavidin. This was followed by addition of 3,3'-diaminobenzidine tetrachloride solution (DAB) from the LSAB+[®] kit to visualise antigen localization. Negative controls involved the primary antibody replaced by bovine serum albumen. Smooth muscle was used as a positive control for α -smooth muscle actin, while tonsillar tissue was used as positive controls for S-100. The testis sections were counterstained with hematoxylin for 30 seconds, washed in water, dehydrated through graded ethanol, cleared in xylene and mounted with DPX permanent mounting media (Sigma-Aldrich Co, MO, USA). Sections were then examined under light microscope. Immunoreactivities to S-100 and α -smooth muscle actin were designated as absent (-), weak (+), moderate (2+) and strong (3+) based on visual examination.

RESULTS

Histology

The testis was ensheathed by a capsule with seminiferous tubules of various sizes and shapes, mostly spherical to oval (Figure 1A). Wedged among adjacent seminiferous tubules was the interstitium containing interstitial Leydig cells and blood vessels. Highly-convoluted seminiferous tubules formed about 80% of testis tissue of the animal with each having a basement membrane lined with Sertoli cells as well as germ cells arranged in successive layers representing different stages of spermatogenesis and spermiogenesis (Figure 1B).

Immunohistochemistry

The main immunohistochemical findings are summarized in table 1.

Alpha smooth muscle actin (α -SMA)

Strong immunoreactivities to α -SMA were observed for the peritubular myoid cells, the testicular capsule and vascular endothelium (Figures 2A and B). The testicular capsule showed more intense reactivity in the inner than in the outer portions (Figure 2B). Moderate immunoreactivities to α -SMA were observed for the straight tubules as well as rete testis (Figures 2C and D). However, the spermatogenic cells, Sertoli cells and Leydig cells were immunonegative to α -SMA.

S-100

Strong immunoreactivities to S-100 were observed for the peritubular myoid cells and testicular capsule (Figures 3B and D). The spermatogenic cells, Sertoli cells, Leydig cells, straight tubules as well as rete testis and vascular endothelium all expressed moderate immunoreactivities to S-100 (Figures 3A and C).

DISCUSSION

The histological features of the testis of the African four-toed hedgehog are similar to those reported for the African greater cane rat, *Thryonomys swinderianus*, (Olukole et al., 2009; Olukole and Obayemi, 2010), the African giant rat, *Cricetomys gambianus*, (Oke, 1982; Oke, 1988) and rodents generally (Bacha and Bacha, 2000; Massanyi et al., 2003; Young et al., 2006). Similar to the case in the African greater cane rat, contractile myoid cells were found lining the peritubular tissue of the seminiferous tubules of the African four-toed hedgehog (Olukole and Obayemi, 2010). However, unlike the case of the African greater cane rat, majority of the seminiferous tubules of the African four-toed hedgehog were highly convoluted (Olukole et al., 2009).

The present study is a new report on the localization of alpha smooth muscle actin (α -SMA) and S-100 in the testis of the African four-toed hedgehog. The more intense immunoreactivity to α SMA observed in the inner portion of the testicular capsule of the African four-toed hedgehog, suggests that contractile activity of the testicular capsule is greater in the inner than in the outer portions of the testicular capsule of the animal. Similar observation has been documented in the rat (Banks et al., 2006). Conversely, Abd-Elmaksoud (2009) reported α SMA-positive reaction to be more in the outer portion of the testicular capsule of the rabbit. α SMA has been reported to be widely distributed throughout the tunica albuginea of the testicular capsule in the avian species such as Sudani duck and pigeon (Abd-Elmaksoud, 2009). It can be inferred that the contractile smooth muscle arrangement observed in the testicular capsule of the African four-toed hedgehog may be essential in the movement of spermatozoa out of the testis of the animal.

The α SMA-positive reaction observed in the testicular peritubular tissue and vasculature in this study has been observed in several mammals and birds (Sekido and Lovell-Badge, 2013; Valdez et al., 2014; Domke et al., 2019). One of the functions of peritubular myoid cells has been shown to be the regulation of Sertoli cell functions in animals (Anthony, 1991). Sertoli cell's stimulation of total protein by peritubular cells have linked to increases in androgen-binding protein production (Hadley et al., 1985).

Hence, peritubular myoid cells of the African hedgehog, due to its strong reactivity to α SMA are expected to collaborate with Sertoli cells in the structural formation and maintenance of the blood-testis barrier in the animal. Collectively, the positive immunoreactivities to α SMA observed for the testicular capsule, the peritubular myoid cells, straight tubules as well as the rete testis of the African four-toed hedgehog is suggestive of a collaborative contractile activity in the movement of spermatozoa produced in the seminiferous tubules into the excurrent ducts of the testis of the animal.

The strong immunoreactivities to S-100 protein observed for the peritubular tissue and Sertoli cells further shows the possibility of a collaborative function by the duo in the maintenance of the blood-testis barrier in the African hedgehog. Similarly, S-100 protein has been localized in the Sertoli cells of various animals includes bull, dog, boar, rat, rabbit, ram, stallion and boar (Riuzzi et al., 2011; Abd-Elmaksoud et al., 2014) as well as in the monkey, buffalo (Cruzana et al., 2003) and humans (Li et al., 2010; West and Watson, 2010). S-100 protein has been shown to regulate cell division and cell morphology in a calcium-dependent manner (Donato, 2001; Abd-Elmaksoud et al., 2014) Also, S-100 protein in the Sertoli cells is assumed to be involved in the microtubule assembly-disassembly as well as in the secretory, protective and absorptive functions of the Sertoli cells of mammals (Cruzana et al., 2003).

The S-100 positive reaction with spermatogenic and Leydig cells of the African four-toed hedgehog suggests that the protein is involved in the processes of spermatogenesis as well as steroidogenesis. S-100 positive reaction has been reported for the Leydig cells of turtle and mammals (Young et al., 2006; Olukole et al., 2018). However, the testicular germ cells as well as the Leydig cells of the rabbit have been shown to be immunonegative to S-100 (Abd-Elmaksoud et al., 2014).

The strong immunoreactivity to S-100 exhibited by the testicular vasculature in this study tallies with other studies that have shown that the endothelial cells of capillaries, veins, and lymphatic vessels are regularly S-100 protein immunoreactive in rat, rabbit, boar, ruminants, European bison and man (Michetti et al., 1985; Amselgruber et al., 1994; Czykier, 1999; Abd-Elmaksoud et al., 2014). Testicular S-100 protein has been reported serve in the prevention of cytoplasmic calcium overload which has been demonstrated to cause cellular apoptosis as well as the induction of mitochondria calcium overload thereby leading to testicular mitochondrial malfunctioning (Orrenius et al., 2003).

CONCLUSION

In conclusion, α SMA and S-100 proteins have active roles in the cytoskeletal structure of testis and physiology of the African four-toed hedgehogs while S-100 protein plays additional and complementary roles in the structural formation and maintenance of the blood-testis barrier as well as in steroidogenesis and spermatogenesis in the animal.

Table 1. Distribution of α SMA and S-100 proteins in the testis of the African four-toed hedgehogs.

ATB	SPC	SC	LC	PMC	TC	VE	ST	RT
α SMA	-	-	-	+++	+++	+++	++	++
S-100	++	++	++	+++	+++	++	++	++

Antibody (ATB); spermatogenic cells (SPC); Sertoli cell (SC); Leydig cell (LC); peritubular myoid cell (PMC); testicular capsule (TC); vascular endothelium (VE); straight tubule (ST); rete testis (RT). Negative reaction (-); moderately positive reaction (++); strongly positive reaction (+++).

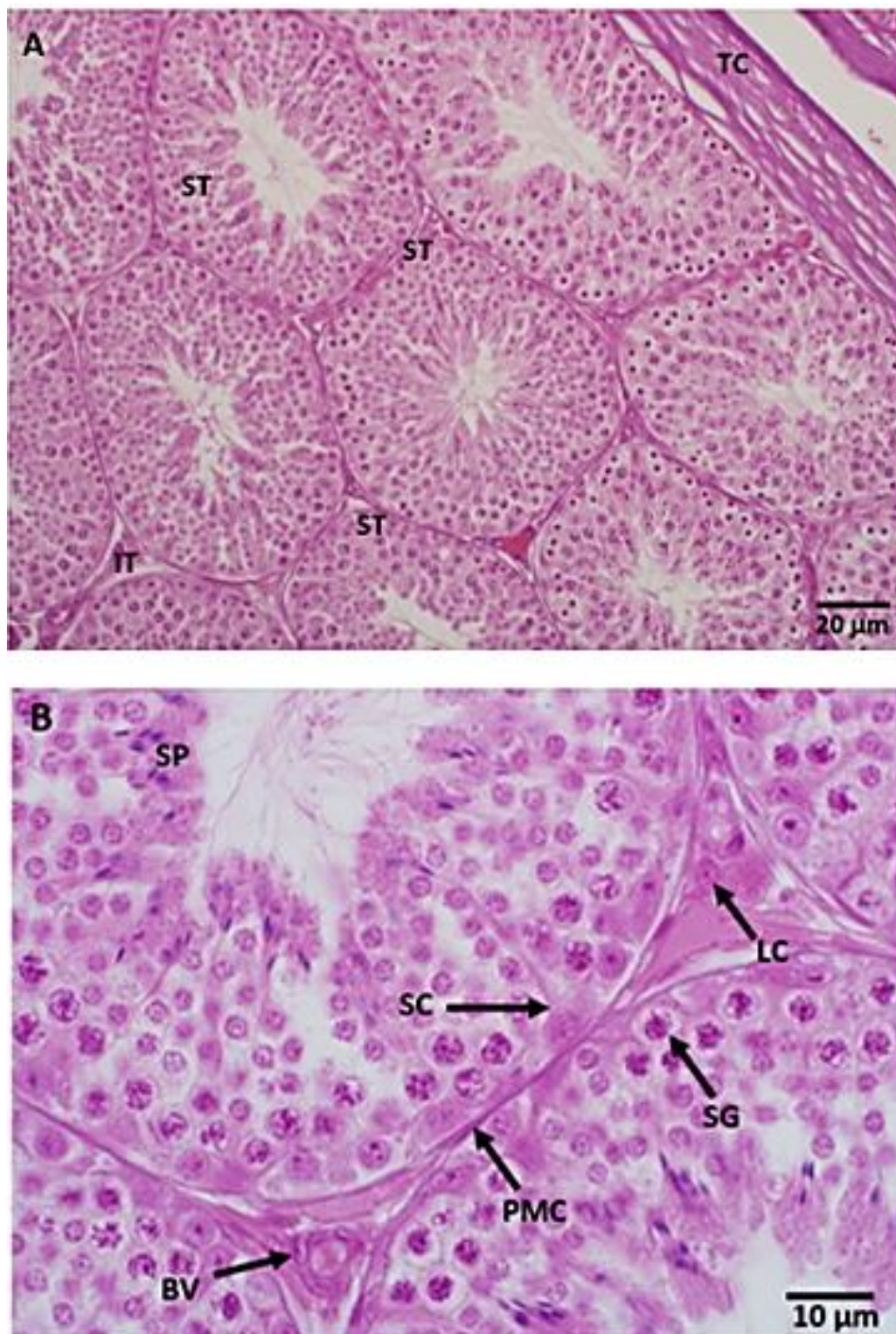


Figure 1. Photomicrographs of the testis of the African four-toed hedgehog (H&E). **A:** testicular capsule (TC), seminiferous tubule (ST) and interstitial tissue (IT). **B:** spermatocyte (SP), Sertoli cell (SC), blood vessel (BV), peritubular myoid cell (PMC), spermatogonium (SG), Leydig cell (LC).

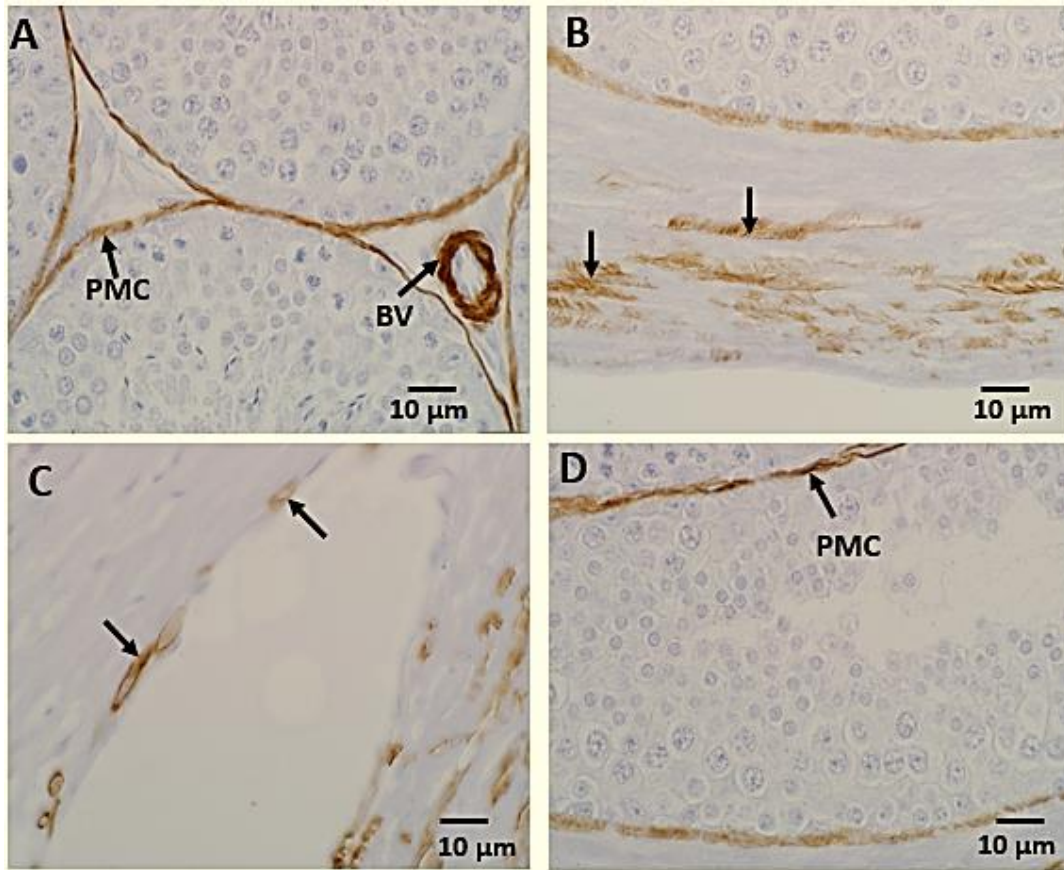


Figure 2. **A:** Localization of alpha smooth muscle actin (α SMA) in the testis of the African four-toed hedgehog. Blood vessel (BV) and peritubular myoid cell (PMC). **B:** Positive reactions (arrows) in testicular capsule. **C:** Positive reactions (arrows) in the rete testis. **D:** Positive reactions (arrows) in the peritubular tissue of the straight tubules (α SMA).

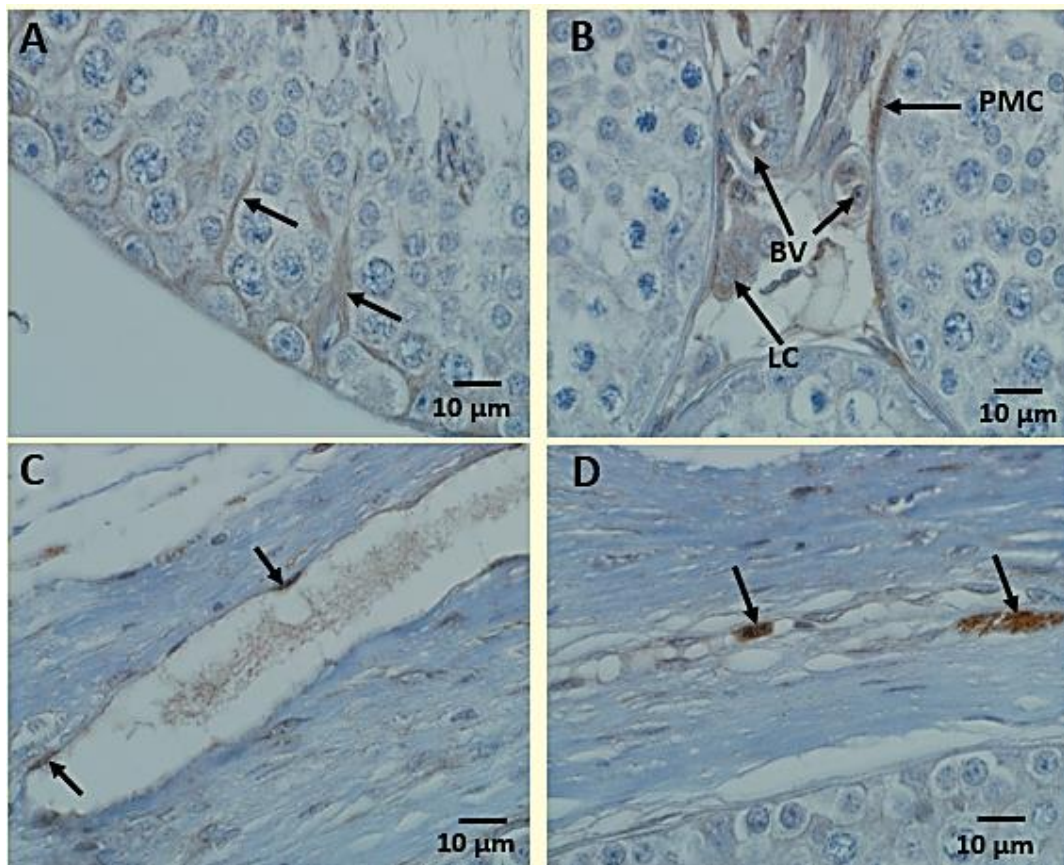


Figure 3. Localization of S-100 protein in the testis of the African four-toed hedgehog. **A:** Positive reaction with the Sertoli cells (arrows). **B:** Positive reactions with the blood vessels (BV), peritubular myoid cell (PMC) and Leydig cell (LC). **C:** Positive reactions (arrows) in the rete testis. **D:** Positive reactions (arrows) in testicular capsule.

DECLARATIONS

Acknowledgement

The authors would like to thank Dr. Kafilat Quadri and Dr Ibrahim Ibiade (Department of Veterinary Anatomy, University of Ibadan, Nigeria) for their help in data collection.

Competing interests

The authors declare that they have no competing interests.

Authors' contributions

Samuel Gbadebo Olukole conceived the study and participated in its design and coordination and drafted the manuscript. Oluwakayode Michael Coker participated in its design and coordination and helped to draft the manuscript. Bankole Olsiji Oke participated in its design and coordination. All authors read and approved the final manuscript.

REFERENCES

- Abd-Elmaksoud A (2009). Comparative expression of laminin and smooth muscle actin in the testis and epididymis of poultry and rabbit. *Journal of Molecular Histology*, 40: 407–416. DOI: <https://doi.org/10.1007/s10735-010-9254-x>
- Abd-Elmaksoud A, Shoeib MB and Marei HES (2014). Localization of S-100 proteins in the testis and epididymis of poultry and rabbits. *Anatomy and Cell Biology*, 47: 180–187. DOI: <https://doi.org/10.5115/acb.2014.47.3.180>
- Aire TA and Ozegebe PC (2007). The testicular capsule and peritubular tissue of birds: morphometry, histology, ultrastructure and immunohistochemistry. *Journal of Anatomy*, 210: 731–740. DOI: <https://doi.org/10.1111/j.1469-7580.2007.00726.x>
- Alkafafy M, Rashedb R and Helal A (2012). Immunohistochemical studies on the bovine lactating mammary gland (*Bos taurus*). *Acta Histochemica*, 114: 87–93. DOI: <https://doi.org/10.1016/j.acthis.2011.02.012>
- Amselgruber WM, Sinowatz F and Erhard M (1994). Differential distribution of immunoreactive S-100 protein in mammalian testis. *Histochemistry*, 102: 241–245. DOI: <https://doi.org/10.1007/BF00268901>
- Anthony CT, Rosselli M and Skinner MK (1991). Actions of the testicular paracrine factor (P-Mod-S) on Sertoli cell transferrin secretion throughout pubertal development. *Endocrinology*, 129: 353–360. DOI: <https://doi.org/10.1210/endo-129-1-353>
- Bacha WJ and Bacha LM (2000). *Color Atlas of Veterinary Histology*. Lippincott Williams and Wilkins, USA.
- Banks FCL, Knight GE, Calvert RC, Turmaine M Thompson CS, Mikhailidis DP, Morgan RJ and Burnstock G (2006). Smooth muscle and purinergic contraction of the human, rabbit, rat, and mouse testicular capsule. *Biology of Reproduction*, 74: 473–480. DOI: <https://doi.org/10.1095/biolreprod.105.044602>
- Bedford JM, Mock OB, Nagdas SK, Winfrey VP and Olson GE (2000). Reproductive characteristics of the African pygmy hedgehog, *Atelerix albiventris*. *Journal of Reproduction and Fertility*, 120 :143–150. DOI: <http://dx.doi.org/10.1530/jrf.0.1200143>
- Cassola F (2016). *Atelerix albiventris*: The IUCN Red List of Threatened Species 2016, [Online] Assessed from: e.T40602A22324217. DOI: <http://dx.doi.org/10.2305/IUCN.UK.2016>
- Coker OM, Olukole SG and Udje OA (2018). Internal and external morphometry of the four-toed hedgehog (*Atelerix albiventris*); Wagner, 1841) in Ibadan, Nigeria. *Animal Research International*, 15(2): 3002–3012. Available at: <https://www.ajol.info/index.php/ari/article/view/187110>
- Couture ÉL, Langlois I, Santamaria-Bouvier A and Benoit-Biancamano M (2015). Cutaneous squamous cell carcinoma in an African pygmy hedgehog (*Atelerix albiventris*) *The Canadian Veterinary Journal*, 56(12):1275–1278. PMID: 26663924
- Cruzana MB, Budipitojo T, De Ocampo G, Sasaki M, Kitamura N and Yamada J (2003). Immunohistochemical distribution of S-100 protein and subunits (S100-alpha and S100-beta) in the swamp-type water buffalo (*Bubalus bubalis*) testis. *Andrologia*, 35: 142–5. DOI: <https://doi.org/10.1046/j.1439-0272.2003.00550.x>
- Czykier E, Sawicki B and Zabel M (1999). Immunocytochemical localization of S-100 protein in the European bison testis and epididymis. *Folia Histochemica Et Cytobiologica*, 37: 83–84. PMID: 10352969
- Domke LM, and Franke WW (2019). The cell–cell junctions of mammalian testes: II. The lamellar smooth muscle monolayer cells of the peritubular wall are laterally connected by vertical adherens junctions—a novel architectonic cell–cell junction system. *Cell and Tissue Research*, 375: 451–482. DOI: <https://doi.org/10.1007/s00441-018-2968-x>
- Donato R (2001). S100: a multigenic family of calcium-modulated proteins of the EF-hand type with intracellular and extracellular functional roles. *The International Journal of Biochemistry and Cell Biology*, 33: 637–668. DOI: [https://doi.org/10.1016/S1357-2725\(01\)00046-2](https://doi.org/10.1016/S1357-2725(01)00046-2)
- Gardhouse S and Eshar D (2015) Retrospective study of disease occurrence in captive African pygmy hedgehogs (*Atelerix albiventris*). *Israel Journal of Veterinary Medicine*, 70 (1):32–36. Available at: <https://pdfs.semanticscholar.org/a04e/654e0dcbe3244b719d69cbd930a5f5e02b.pdf>
- Girgiri I, Olopade JO and Yahaya A (2015). Morphometrics of foramen magnum in African four-toed hedgehog (*Atelerix albiventris*). *Folia Morphologica*, 74:188–191. DOI: <https://doi.org/10.5603/FM.2015.0030>
- Girgiri IA, Yahaya A, Gambo BG, Majama YB and Sule A (2016) osteomorphology of the appendicular skeleton of four-toed African Hedgehogs (*Atelerix albiventris*) part (2): pelvic limb. *Global Veterinaria*, 16 (5): 413–418. DOI: <https://doi.org/10.5829/idosi.gv.2016.16.05.10352>
- Hadley MA, Byers SW, Sua´rez-Quian CA, Kleinman HK and Dym M (1985). Extracellular matrix regulates Sertoli cell differentiation, testicular cord formation, and germ cell development *in vitro*. *Journal of Cell Biology*, 101(4): 1511–1522. DOI: <https://doi.org/10.1083/jcb.101.4.1511>
- Henke J, Reinert J, Preissel AK and Radtke-Schuller S (2007). Partially antagonisable anaesthesia of the small hedgehog tenrec (*Echinops telfairi*) with medetomidine, midazolam and ketamine. *Journal of Experimental Animal Science*, 43(4): 255–264. DOI: <https://doi.org/10.1016/j.jeas.2006.09.003>
- Kingdon J (1997). *The Kingdon's Field guide to African Mammals*. San Diego, California: Academic press. 464pp
- Li ZH, Dulyaninova NG, House RP, Almo SC and Bresnick AR (2010). S100A4 regulates macrophage chemotaxis. *Molecular Biology of the Cell*, 21: 2598–2610. PMID: 20519440
- Massanyi P, Jancova A and Uhrin V (2003). Morphometric study of male reproductive organs in the rodent species *Apodemus sylvaticus* and *Apodemus flavicollis*. *Bulletin of the Veterinary Institute in Pulawy*, 47: 133–138. Available at: <http://www.piwet.pulawy.pl/jvetres/images/stories/pdf/20031/20031133138.pdf>

- Michetti F, Lauriola L, Rende M, Stolfi VM, Battaglia F and Cocchia D (1985). S-100 protein in the testis. An immunochemical and immunohistochemical study. *Cell and Tissue Research*, 240: 137-142. DOI: Available at: <https://link.springer.com/article/10.1007/BF00217566>
- Mori M and O'Brien SE (1997). Husbandry and Medical Management of African Hedgehogs. *Iowa State University Veterinarian*, 59(2): 64-71. Available at: https://lib.dr.iastate.edu/iowastate_veterinarian/vol59/iss2/5
- Oke BO (1982). Some studies on the reproductive organs of the African giant rat (*Cricetomys gambianus*, Waterhouse) during the climatic seasons at Ibadan. M.Sc. thesis, Department of Veterinary Anatomy, University of Ibadan, Nigeria.
- Oke BO (1988). Some aspects of the reproductive biology of the African giant rat (*Cricetomys gambianus*, Waterhouse). Ph.D. thesis, Department of Veterinary Anatomy, University of Ibadan, Nigeria
- Olukole SG and Obayemi TE (2010). Histomorphometry of the testis and epididymis in the domesticated adult African greater cane rat (*Thryonomys swinderianus*). *International Journal of Morphology*, 28: 1251-1254. Available at: <https://pdfs.semanticscholar.org/a994/742d61a0686dde8aa9b28834908841276dab.pdf>.
- Olukole SG and Oke BO (2018). Sertoli cell junctions during active spermiogenesis in the African sideneck turtle (*Pelusios castaneus*): Implications for the blood-testis barrier. *International Journal of Veterinary Science*, 7 (2): 106-112. Available at: <http://www.ijvets.com/pdf-files/Volume-7-no-2-2018/106-112.pdf>
- Olukole SG, Coker OM and Oke BO (2020). Immunohistochemical studies of α SMA in the epididymis of African four-toed hedgehog (*Atelerix albiventris*). *Folia Veterinaria*, 64(1): 11-18. DOI: <https://doi.org/10.2478/fv-2020-0002>
- Olukole SG, Oyeyemi MO and Oke BO (2009). Biometrical observations on the testes and epididymis of the domesticated adult African great cane rat (*Thryonomys swinderianus*). *European Journal of Anatomy*, 13: 71-75. Available at: <http://www.eurjanat.com/web/paper.php?id=09020071>
- Orrenius S, Zhivotovsky B and Nicotera P (2003). Regulation of cell death: The calcium- apoptosis link. *Nature Reviews Molecular Cell Biology*, 4: 552-565. DOI: <https://doi.org/10.1038/nrm1150>
- Reeve N (1994). Hedgehogs. Elsevier Science & Technology Books, London. pp. 1-313. ISBN: 085661081X. Available at <https://www.abebooks.com/book-search/title/hedgehogs/author/nigel-reeve/book/>
- Riuzzi F, Sorci G and Donato R (2011). S100B protein regulates myoblast proliferation and differentiation by activating FGFR1 in a bFGF-dependent manner. *Journal of Cell Science*, 124: 2389-400. PMID: 21693575.
- Santana EM, Jantz HE and Best TL (2010). *Atelerix albiventris* (Erinaceomorpha: Erinaceidae). *Mammalian Species*, 42(857): 100. DOI: <https://doi.org/10.1644/857.1>
- Sekido R and Lovell-Badge R (2013). Genetic control of testis development. *Sexual Development*, 7(1-3): 21-32. DOI: <https://doi.org/10.1159/000342221>
- Smith AJ (1992). Husbandry and medicine of African hedgehogs (*Atelerix albiventris*). *Journal of Small Exotic Animal Medicine*, 2: 21-28.
- Symonds MRE (1999). Life histories of the Insectivora: the role of phylogeny, metabolism and sex differences. *Journal Zoology*, 249: 315-337. DOI: <https://doi.org/10.1111/j.1469-7998.1999.tb00768.x>
- Valdez DJ, Cortez MV, Della-Costa NS, Lèche A, Hansen C, Navarro JL and Martella MB (2014). Seasonal changes in plasma levels of sex hormones in the Greater Rhea (*Rhea americana*), a South American Ratite with a complex mating system. *PLoS ONE*, 9(5): e97334. DOI: <https://doi.org/10.1371/journal.pone.0097334>
- West NR and Watson PH (2010). S100A7 (psoriasin) is induced by the proinflammatory cytokines oncostatin-M and interleukin-6 in human breast cancer. *Oncogene* 29: 2083-2092. PMID: 20101226
- World Heritage Encyclopedia (WHE) (2017). Four-toed hedgehog. World Library Foundation. http://www.worldbooklibrary.org/articles/eng/Four-toed_hedgehog. (Accessed May, 2017).
- Young B, Lowe JS, Stevens A and Heath JW (2006). Wheater's Functional Histology: A text and colour atlas, 5th edition. Elsevier Limited, Churchill Livingstone. Pp. 346-358.