



Successful Surgical Management of Corneo-conjunctival Dermoid Cyst with Bilateral Nasal Choristoma in a Red Kandhari Calf

Vilas Aher, Bhagyashree Bhadane, Pradeep Ramchandra Balage*, Gajanan Dhage, Govind Gangane, Ankit Asaramji Mate and Devidas Shankar Lokhande

Department of Veterinary Surgery and Radiology, College of Veterinary and Animal Science, Parbhani, Maharashtra- India

*Corresponding author's Email: pradeep.balage752@gmail.com

ABSTRACT

An old Red Kandhari calf presented at teaching veterinary clinical complex, veterinary college Parbhani with corneo-conjunctival haired masses on the left eye and bilateral nasal growth at nasolabial planum since birth. As the mass was completely covering on cornea due to which vision was hindered completely after physical examination and considering the health status of the calf the surgery was scheduled. The masses were surgically excised from the cornea and bulbar conjunctiva of eye and the left and right side of the dorsomedial nasolabial planum. Then the eye was flushed with normal saline and the tissue of both corneo-conjunctival and nasal were stored in 10% formalin later histopathology of the excised tissue confirmed as a unilateral corneoc-onjunctival dermoid with ectopic lacrimal glands and bilateral nasal choristomas with loose stroma and hair follicle. Two months of follow up was done where there was no reoccurrence of the growth observed. Surgery was curative and healing was uneventful.

Key words: Calf, Corneoc-onjunctival dermoid, Nasal choristoma

ORIGINAL ARTICLE
 PII: S232245681800012-8
 Received: 08 Nov 2018
 Accepted: 06 Dec 2018

INTRODUCTION

Ocular dermoid is a congenital defect recognized in animals characterized by skin like appendages present on the eye. These represent histologically normal Island of skin but misplaced to other location usually arising on the limbus, conjunctivae and cornea (Jena et al., 2015). It is believed that these cysts originate from an incarceration and subsequent growth of embryonic epithelial cells during the closure of the neural tube, and therefore, most of these lesions occur along the median line (Tunio et al., 2016). However, there are reports of acquired dermoid cysts, secondary to traumatic epithelial dislocations they are readily diagnosed because they appear as a piece of skin attached to the cornea, sclera, conjunctiva and eyelids (Rashmi et al., 2018) and they usually occurred unilaterally. Most dermoids are quite superficial and involved the epithelium and very superficial stroma. Choristomas are benign, congenital lesions that consist of an over growth of normal tissue in an abnormal location (Rashmi et al., 2018). Dermoids are choristomatous abnormalities that often arise in the ocular region. Bilateral ocular dermoids have been found in animals (Aher et al., 2017). However, ocular dermoids are not common in cattle with their prevalence estimated at 0.002% (Kilic et al., 2016). This paper reports a case of unilateral corneconjunctival dermoids in a calf in conjunction with bilateral nasal choristomas.

CASE REPORT

History and initial clinical findings

An old Red Kandhari calf (aged one month) was presented with an abnormal appearance of left eye since birth. A large fleshy mass was attached to the dorsal and ventral part of cornea and bulbar conjunctiva spacing on cornea with a large number of superiorly directed hairs arising from the surface of the mass (Figure 1).

The calf exhibited moderate blepharospasm and watery discharge from affected eye. Superficial corneal ulceration was present on the cornea as a result of trichiasis. The corneo-conjunctival dermoid was extending up to medial canthus of the left eye. No other ocular abnormalities were detected in the eye. A nodular skin mass was also present on the left and right dorsomedial aspect of the nasolabial planum of both the nostrils (Figure 2). The clinical diagnosis was unilateral corneal dermoid and bilateral nasal choristomas.

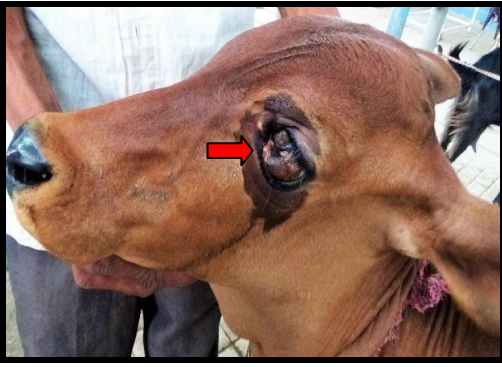

Figure 1. Corneoconjunctival dermoid in one month old Red Kandhari calf before surgery at COVAS Veterinary Hospital

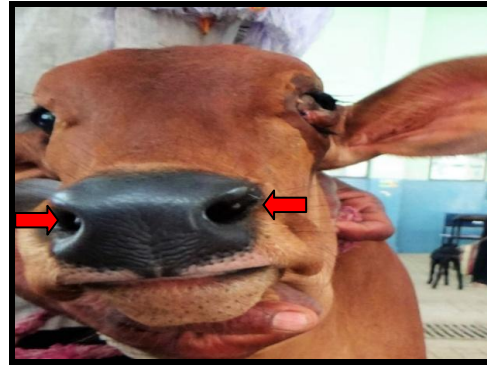


Figure 2. On physical examination observed Bilateral nasal growths on nasolabial planum in calf before surgery at COVAS Veterinary Hospital

Surgical procedure

The calf weighed 30 kg, was in good level of body condition and no further abnormalities were detected on physical examination. Corrective surgery was performed under mild sedation with injection Pentazocine lactate 0.5 mg/kg body weight intravenously followed by supra orbital and Peterson nerves block with 2% lignocain hydrochloride (Figure 3). The dermoids were excised by superficial keratectomy with Bard Parker blade (No. 11) at both dorsal and ventral aspect of cornea and bulbar conjunctiva (Figure 3).

The nasal masses were also excised (Figure 4). All excised tissue was preserved in 10% formalin for histopathological examination. Later cornea was cauterized by 1% silver nitrate and topically applied Tobramycin eye drops two times daily for two weeks (Figure 5). Postoperatively a course of antibiotic gentamycin 3mg/kg body weight, intramuscular, cadistin 0.2mg/kg body weight, intramuscular and Melonex 0.5mg/kg body weight, intramuscular along with this to accelerate the healing injection of vitamin A 10000 IU/kg body weight, intramuscular was given (Figure 5). Ocular and nasal healing was uneventful with prominent corneoconjunctival granulation tissue observed on 6th days postoperatively, which was noticed to be largely resolved by the six-week follow-up examination (Figures 5 and 6).

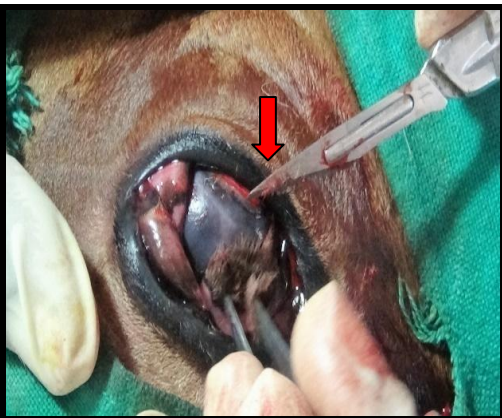

Figure 3. During surgery performing superficial keratectomy to excise the growth of dermoids in calf at COVAS Veterinary Hospital

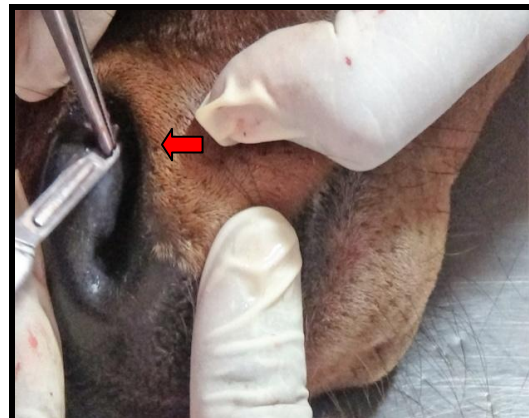

Figure 4. Excision of nasal growths from its base in calf at COVAS Veterinary Hospital




Figure 5. Complete recovery after six weeks of surgery at COVAS Veterinary Hospital

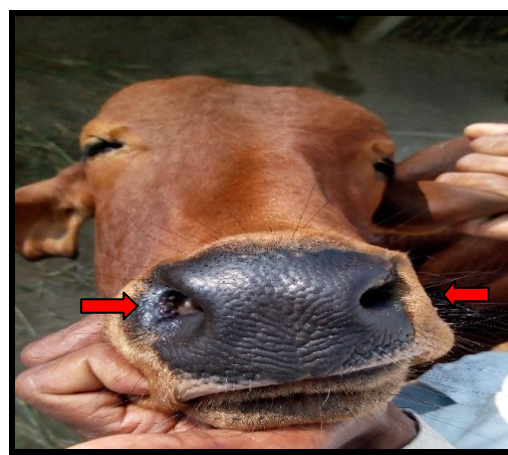


Figure 6. No reoccurrence of the nasal growth after six weeks of surgery at COVAS Veterinary Hospital

Histopathological examination

The corneal lesion exhibited a moderately well delineated but nonencapsulated raised mass comprised of moderately hyperplastic, keratinizing stratified squamous epithelium overlying a thick collagenous stroma, which merged with conjunctival tissue containing submucosal glandular tissue. The corneal mass contained numerous, large, well developed hair follicles and adnexal structures superficially. A band of abortive hair follicles and adnexa was identified as haphazardly arranged clusters of epitheliums, in the absence of hair bulbs, intermingled with tortuous lumen of apocrine glands beneath the productive follicles (Figure 7). This was accompanied by myxomatous stroma and a minimal neutrophilic and eosinophilic inflammatory infiltrate, in addition to this ectopic lacrimal gland was also identified. Histopathology of the excised nasal tissue was similar and characterized by moderately well-delineated but nonencapsulated, raised masses. These were comprised of moderately hyperplastic, keratinizing stratified squamous epithelium over lying large regularly arranged hair follicles (Figure 8) and confirmed as nasal choristoma. Morphologic diagnosis was bilateral corneo-conjunctival dermoids with ectopic lacrimal glands and bilateral nasal choristomas.

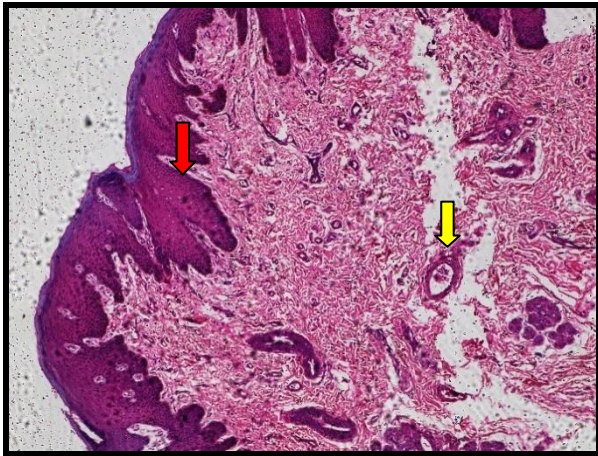


Image 8. Nasal choristoma showing nasal epithelium with loose stroma (red arrow) and having hair follicles (yellow arrow) (H and E stain x100)

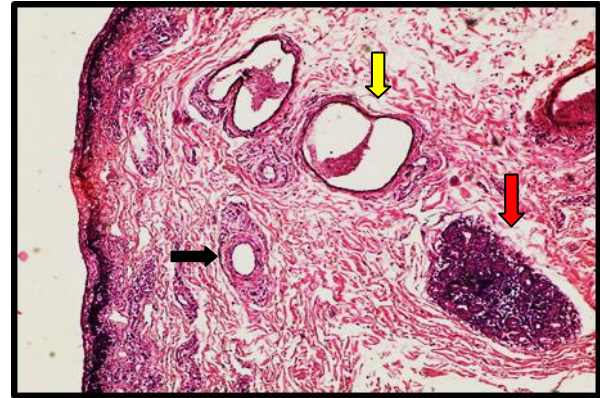


Image 7. Corneal conjunctival dermoid cyst with young growing collagen fibres and lacrimal gland (red arrow) characterized by the presence of hair follicles (yellow arrow) and an associated apocrine gland (black arrow) (H and E stain x 100).

DISCUSSION

Metaplasia of mesenchyme (of primarily neural crest origin), resulting in abnormal differentiation of the surface ectoderm, is considered the most likely mechanism. The resulting dermoid consists of ectodermal elements (keratinized epithelium, hairs, sebaceous and apocrine glands. and mesenchymal elements (fibrous tissue, fat and cartilage) combined in different proportions (Rashmi et al., 2018). Our finding in this case was in agreement with Jena et al. (2015) who reported that Holstein Friesians cross bred calf affected with unilateral dermoid on right eye. Dermoid may be located in the third eyelid, cornea, conjunctiva, corneal conjunctival junction and limbus region in this study conjunctivitis these findings were correlated with study of Tunio et al. (2016) who observed that skin tissue and hair attached to the cornea and frequently irritate eye of the animal which leads to conjunctivitis

Dermoid have been reported in many breeds of cattle and can be unilateral or bilateral ocular dermoids in cattle are not common, with an estimated prevalence of 0.002%–0.4% (Rashmi et al., 2018). Ocular dermoids have been reported in cattle of many breeds worldwide, with a similar low prevalence in all breeds other than the Hereford. There are otherwise few reports of unilateral ocular dermoids in calves, each describing single or low numbers of animals and only one reporting a nasal tumor-like growth (Kilic et al., 2016). Of these bilateral cases, inferonasal corneo-conjunctival dermoids were most commonly reported, followed by nasal dermoids (Kilic et al., 2016). Ocular dermoids may be associated with other congenital ocular or multi organ abnormalities (Tunio et al., 2016). Ectopic lacrimal tissue may appear in combination with an ocular dermoid as in this case report and previously reported in cattle (Aher et al., 2017). The ectopic lacrimal tissue in this calf may have represented misplacement of the nictitans gland or additional lacrimal tissue development (Kilic et al., 2016).

The ectopic lacrimal tissue in this calf may have represented misplacement of the nictitans gland or additional lacrimal tissue development. Choristomas are known to grow, with the rate accelerated by trauma, irritation or puberty, in humans. Malignant degeneration is rare in ocular choristomas but transformation of ectopic lacrimal tissue into adenocarcinoma and pleomorphic adenoma has been reported in humans (Rashmi et al., 2018). Cranial meningocele with bilateral nasal choristoma in a cow calf have been reported in calf where the variable staged hyaline and cartilaginous tissue along with young growing fibrous connective tissue seen in the nasal choristoma (Aher et al., 2017). A tumor-like

growth at the entrance of the left nasal passage in association with bilateral corneal and eyelid dermoids in a Rathi calf (Rashmi et al., 2018). Histopathologic examination was not performed on the nasal masses in either of these two reports.

The combination of congenital ocular and nasal abnormalities in this calf is compatible with the intimate early developmental origin of the optic and nasal regions and a common abnormality in neural crest migration whether this abnormality has a genetic basis or not is less clear (Aher et al., 2017). Superficial keratectomy is required to surgically excise a corneal dermoid although the depth of the dermoid within the cornea cannot be ascertained by ophthalmic examination until surgery is undertaken (Rashmi et al., 2018). In the case of large corneal dermoids, surgical excision should be performed early in the life of the patient to achieve optical improvement and allow functional development of the eye.

DECLARATIONS

Acknowledgements

Authors would like to thank Dr. Moregavkar for his contribution in Histopathological examinations.

Author's contribution

P.R. Balage, B. Bhadane and V. Aher performed surgery and written article. G. Dhage, A.A. Mate and D.Sh. Lokhande helped during surgery and writing article. And G. Gangane contributed for histopathological examinations.

Competing interest

The authors declare that they have no conflict of interest with respect to the research, authorship, and/or publication of this article, the author declares that he has no competing interests.

REFERENCES

- Aher VD, GP Dhage, GR Gangane and Pradeep RB (2017). A Successful Surgical Repair of Cranial Meningocele with Bilateral Nasal Choristoma in a Calf, *International Journal of Veterinary Science*, 6(3): 141-143.
- Alam MM and Rahman MM (2012). A three years retrospective study on the nature and cause of ocular dermoids in cross-bred calves. *Open Veterinary Journal*, 2:10-14.
- Brunedall DK, Ward DA, Kerr LA and Newman JS (2008). Bilateral corneconjunctival dermoids and nasal choristomas in a calf. *Veterinary Ophthalmology*, 11(3): 202-206.
- Jena B, Ahmed A and Pagrut NK (2015). Surgical management of islands of ocular dermoids in a Holstein Friesian cross bred calf—a case study. *Journal of Livestock Science*, 6:1-3.
- Kilic N, Toplu N and Epikmen ET (2016). Surgical Treatment of Corneal Large Dermoid in a Simmental Calf. *Acta Scientiae Veterinariae*, 40(2): 1041.
- Nijhawan N, Morad Y, Seigel-Bartelt J and Levin AV (2002). Caruncle abnormalities in the oculo-auriculo-vertebral spectrum. *American Journal of Medical Genetics*, 113(4): 320-325.
- Rashmi, Tamilmahan P, Singh P and Prabhakar (2018). Surgical management of dermoid cyst in a cross bred calf. *Journal of Entomology and Zoology Studies*, 6(2): 2574-2576. Available at: <http://www.entomoljournal.com/archives/2018/vol6issue2/PartAC/6-1-345-481.pdf>
- Tunio A, Bughio S, Abro SH, Kalhoru DH and Meghmon AA (2016). Eye dermoid in a thari breed cattle calf and its surgical management: A case study. *Pakistan Journal of Agriculture, Agricultural Engineering and Veterinary Sciences*, 32(2): 295-299.