



Effect of *Crescentia cujete* (L.) Fruit Extract as a Thread-Coating Material for Suture Implant in Rat Skin

Ria Utami^{1,2} , Sitarina Widyarini³ , Bambang Sutrisno³ , Yos Adi Prakoso^{2*} , and Micco Joshua Apriano Pangaribuan^{1,2}

¹Master's Program in Veterinary Sciences, Faculty of Veterinary Medicine, Universitas Gadjah Mada, Yogyakarta, Indonesia

²Department of Pharmacology, Faculty of Veterinary Medicine, University of Wijaya Kusuma Surabaya, Surabaya, Indonesia

³Department of Pathology, Faculty of Veterinary Medicine, Universitas Gadjah Mada, Yogyakarta, Indonesia

*Corresponding author's Email: yos.vet.docter@gmail.com

ABSTRACT

Thread coatings on suture implants are designed to enhance biocompatibility and biodegradability, supporting wound healing by reducing inflammation and accelerating collagen density. Ascorbic acid, an antioxidant found in specific coatings, can help to increase collagen density. One specific antioxidant is derived from the calabash fruit (*Crescentia cujete*-Linnaeus). Using a rat model, this study evaluated the effectiveness of calabash fruit extract (CFE) as a suture material for skin implants. The experiment was conducted with 16 female rats, each 12 months old and weighing 300 grams. The rats were randomly divided into four groups, including P1 (control), P2 (cannula), P3 (implanted with polydioxanone), and P4 (implanted with polydioxanone coated with 100% calabash fruit extract). The sutures were implanted on both the left and right sides of the rats' back skin. Skin samples were collected on days 3 and 7 and analyzed for histopathology, collagenization, and the immunoreactivity of interleukin-6 and fibroblast growth factor. Group P4 showed better histopathological score, collagenization, and the percentage of IL-6's immunoreactivity and FGF than the other groups. Histopathological analysis indicated reduced inflammation, smaller intradermal wound diameters, and increased fibroblasts and collagen density in P4 compared to P3 (the group with PDO without CFE coating). Additionally, P4 displayed better IL-6 and FGF immunoreactivity than the other groups. This study demonstrated that CFE can enhance skin quality following suture implantation. The significant benefits of CFE on skin histopathology, collagenization, IL-6, and FGF immunoreactivity offer promise for its potential applications in wound healing.

Keywords: Calabash fruit extract, Fibroblast growth factor, Histopathology, Interleukin-6, Suture implant

INTRODUCTION

Skin is essential for humans and animals, acting as a barrier and maintaining a fluid balance. The skin integrity decreases over time due to the ultraviolet exposure (Gromkowska-Kępcia et al., 2021), fluid imbalance (Wilson et al., 2023), wounds (Prakoso et al., 2021), and ageing (Bonifant and Holloway, 2019), and some cosmetic procedures may be needed to improve it (Borrelli, 2018). A suture implant is a cosmetic surgical procedure designed to enhance collagen density and reorganize the extracellular matrix (Ernanda et al., 2024). The type of suture and its coating materials can beneficially affect the outcome of suture implants, particularly in terms of hypersensitivity reactions with the skin (Selvi et al., 2016). Such hypersensitivity typically triggers an inflammatory response characterized by increased eosinophils (Ye et al., 2014).

An increase in eosinophils due to an inflammatory reaction in the skin often stimulates the synthesis of pro-inflammatory cytokines, especially interleukin 6 (IL-6) (Villarreal-González et al., 2024). Interleukin-6 is crucial in activating cells involved in wound healing, including fibroblasts and endothelial cells, which contribute to the formation of connective tissue (Duan and Yu, 2023) and vascularization around the suture implant (Johnson et al., 2020). However, suppose the IL-6-mediated inflammatory response is robust. In that case, it can hinder the function of fibroblast growth factor (FGF), which is vital for healthy tissue regeneration (Prudovsky, 2021) and can lead to scar tissue formation or fibrosis (Antar et al., 2023). Fibroblast growth factor supports the wound healing mechanism through its capacity to promote fibroblast proliferation, collagen synthesis, angiogenesis, extracellular matrix formation, and tissue regeneration (Ganesha et al., 2019). Therefore, selecting the appropriate type of suture and coating is essential to maximize the healing process and minimize infection and adverse tissue reactions (Ernanda et al., 2024).

Thread coatings on suture implants are designed to enhance performance and promote wound healing by reducing infection risk and improving biocompatibility (Sprowson et al., 2018; He et al., 2023). One of the thread coating materials uses ascorbic acid (Edwards et al., 2022). Ascorbic acid is an antioxidant that boosts the FGF, promoting tissue regeneration and collagenization. Additionally, ascorbic acid can reduce IL-6 levels, preventing severe inflammation and inhibiting skin healing (Ye et al., 2014).

In tropical regions like Indonesia, natural sources of ascorbic acid, such as the calabash fruit, are underutilized despite their potential as a treatment for pneumonia (Prakoso et al., 2024), immunostimulant (Wongkar et al., 2024), and antiinflammation (Hidayah et al., 2023). This fruit, which ranges in colour from green to brass and typically has a diameter of about 25 cm, features white pulp (Parvin et al., 2015). The calabash fruit contains antioxidant, anti-

inflammatory, and antibacterial compounds, making it a suitable candidate as a thread coating material for suture implants (Prakoso et al., 2024). The current study aimed to evaluate the efficacy of the calabash fruit extract (CFE) as a thread-coating material on suture implants in rat models.

MATERIALS AND METHODS

Ethical approval

Animal experiments received approval from the ethical clearance committee of the Research Institute of the Faculty of Dentistry at Airlangga University, Surabaya, under registration number 1026/HRECC.FODM/X/2024.

Time and place of the study

The study was conducted from October to December 2024. The extraction and animal experimentations were performed at the Pharmacology Laboratory of the Faculty of Veterinary Medicine at Wijaya Kusuma University, Surabaya, Indonesia. Histopathology and immunohistochemistry were performed in the Laboratory of Pathology, Faculty of Veterinary Medicine, Universitas Gadjah Mada, Yogyakarta, Indonesia.

Preparation and extraction of calabash fruit

A calabash fruit with a yellowish-green color and a diameter of approximately 40 cm was obtained from the plant market in Surabaya. The fruit was extracted using the maceration method. The pulp of the fruit was immersed in 70% alcohol at a ratio of 1:4 (fruit to solvent). The maceration process was performed three times, with each extraction lasting 24 hours. The resulting product was then evaporated using an evaporator at 69°C until a thick extract was collected (Wilujeng et al., 2022). The calabash fruit extract (CFE) was then stored at 4°C.

The level of ascorbic acid of CFE was measured following Sagrin et al. (2019). Before the test, a standard ascorbic acid solution was prepared. Ten grams of the extract were combined with a metaphosphoric acid and acetic acid solution until the total volume reached 200 mL. Next, indophenol reagent was added until the solution changed colour to pink for at least five seconds. The results were then measured using the following equation: ascorbic acid per 100 grams of sample (mg) = $X \times A \times (V/Y) \times (100/w)$. Where, X (volume of indophenol used to titrate the sample), A (volume of indophenol used to titrate the standard of ascorbic acid), V (total volume of solution), Y (total volume of the sample used in titration until the solution changes to a pink colour), w (weight of the sample). Moreover, the levels of flavonoids, alkaloids, tannins, saponins, and triterpenoids were tested following the study of Ajuru et al. (2017).

Thread-coating procedure

The polydioxanone (PDO; Whitemedience, South Korea) was soaked using CFE for 5 minutes until the thread colour changed, similar to the CFE. The coated PDO was then pasteurized using high temperature short time (HTST) (Donalisio et al., 2018). Before HTST pasteurization, the coated PDO was inserted into the sterile plastic bag and soaked inside the waterbath (Mimmert, Indonesia) at 72°C for 15 seconds. The thread was used directly for suture implant after being processed.

Study design

The experiment used 16 female Sprague-Dawley rats, aged between 11-12 months and weighing approximately 300 grams. The rats were housed individually in cages and had access to water and food *ad libitum*. The rats were divided into four groups, including control with normal skin (P1), skin stabbed using a cannula (P2), skin implanted with PDO (P3), and skin implanted with PDO coated with CFE (P4). Before the suture implant, the rats were anaesthetized intramuscularly with a combination of ketamine (100 mg/kg BW, Agrovmarket, Peru) and xylazine (2 mg/kg BW, Agrovmarket, Peru, Sotoudeh and Namavar, 2022). The hair on the outer side of the spine was shaved using an electric pet trimmer (Electric Pet Trimmer, Indonesia). The area was then disinfected with 70% alcohol. Sutures measuring 2 cm in length were inserted on both the right and left sides of the rats' backs.

Macroscopy assessment

The macroscopy of the skin, including swelling and redness, was recorded after a suture implant using a scoring system. This system was based on the previous study conducted by Plavec et al. (2020) and is defined as follows: 1 (normal, no swelling or redness observed); 2 (mild, slight swelling with an area less than 5 mm and pink skin colour); 3 (minimal, swelling with an area between 5-10 mm and red skin colour); 4 (moderate, swelling with an area between 10-20 mm and violet skin colour); 5 (severe swelling with an area greater than 20 mm and violet skin colour).

Skin sample collection

The rats' skin was collected on days 3 and 7. Before skin collection, the rats were euthanized using lethal doses of ketamine (150 mg/kg BW, Rebuelto et al., 2002). Ketamine was injected intraperitoneally. Skin samples were cut, attached to the cardboard, and soaked in 10% neutral buffered formalin (NBF) for 24 hours.

Histopathological investigation

After 24 hours of fixation with 10% NBF, the skin samples were dehydrated using graded alcohol and xylene before being embedded in liquid paraffin. The paraffin blocks were then sectioned with a microtome to obtain a thickness of 5 µm. The resulting slides were prepared for histopathology using H&E staining. The staining was conducted following

the method described by [Feldman and Wolfe \(2014\)](#). Additionally, the slides were processed for collagen staining using the Mallory staining technique ([Castro et al., 2020](#)).

Immunohistochemistry

The skin sample slides were dehydrated using graded alcohol, xylene, and phosphate-buffered saline, and then blocked with 1% skim milk in PBS ([Prakoso et al., 2021](#)). The slides were stained with mouse antibodies: anti-IL-6 (Cat. No. sc-130326; Santa Cruz Biotechnology Inc.) and anti-FGF (Cat. No. sc-55520; Santa Cruz Biotechnology Inc.), following the staining protocol outlined by [Prakoso et al. \(2020\)](#). The anti-IL-6 antibody was diluted 1:100, and the anti-FGF antibody was diluted 1:250 in the primary antibody diluent (Cat. No. AR9352; Leica Biosystems).

Data analysis

The skin histopathology, collagenization, and immunohistochemistry data were then analyzed using SPSS version 26 (IBM Statistics, USA). This study used the Kruskal-Wallis and Mann-Whitney U tests for data analysis. The Kruskal-Wallis test was used 95% confidence level.

RESULTS

The results of biochemical determination were consisted of ascorbic acid (7.85 ± 2.59 mg/kg), flavonoids (8.29 ± 3.04 mg/kg), alkaloids (20.20 ± 3.94 mg/kg), tannins (6.12 ± 0.19 mg/kg), saponins (1.08 ± 0.75 mg/kg) and phenolic (1.53 ± 3.04 mg/kg). Moreover, the results demonstrated that the suture implant induces swelling and redness on the skin, which was observed macroscopically. Significant differences regarding swelling and redness of the skin after suture implant were found between groups P3 and P4 compared to P1 ($p < 0.05$). Interestingly, the swelling and redness scores for P3 and P4 were not significantly different from each other ($p > 0.05$). Additionally, on day 7, the swelling and redness scores for P3 and P4 did not differ from those of groups P1 and P2 ($p > 0.05$; Table 1 and Figure 1), indicating a notable healing process following the suture implant.

Table 1. Macroscopy score of 11-12-month-old Sprague-Dawley rats' skin after suture implant on days three and seven

Parameter	Day	Group			
		P1	P2	P3	P4
Swollen	3	1.00 ± 0.00^a	1.00 ± 0.00^a	2.00 ± 0.00^b	2.00 ± 0.00^b
	7	1.00 ± 0.00^a	1.00 ± 0.00^a	1.00 ± 0.00^a	1.00 ± 0.00^a
Redness	3	1.00 ± 0.00^a	1.00 ± 0.00^a	1.75 ± 0.50^b	1.50 ± 0.57^b
	7	1.00 ± 0.00^a	1.00 ± 0.00^a	1.00 ± 0.00^a	1.00 ± 0.00^a

P1: Control with normal skin; P2: Skin stabbed using a cannula; P3: Skin implanted with polydioxanone; P4: Skin implanted with polydioxanone coated with Calabash fruit extract. ^{a,b,c} Different superscript letters indicated significant differences in each row ($p < 0.05$).

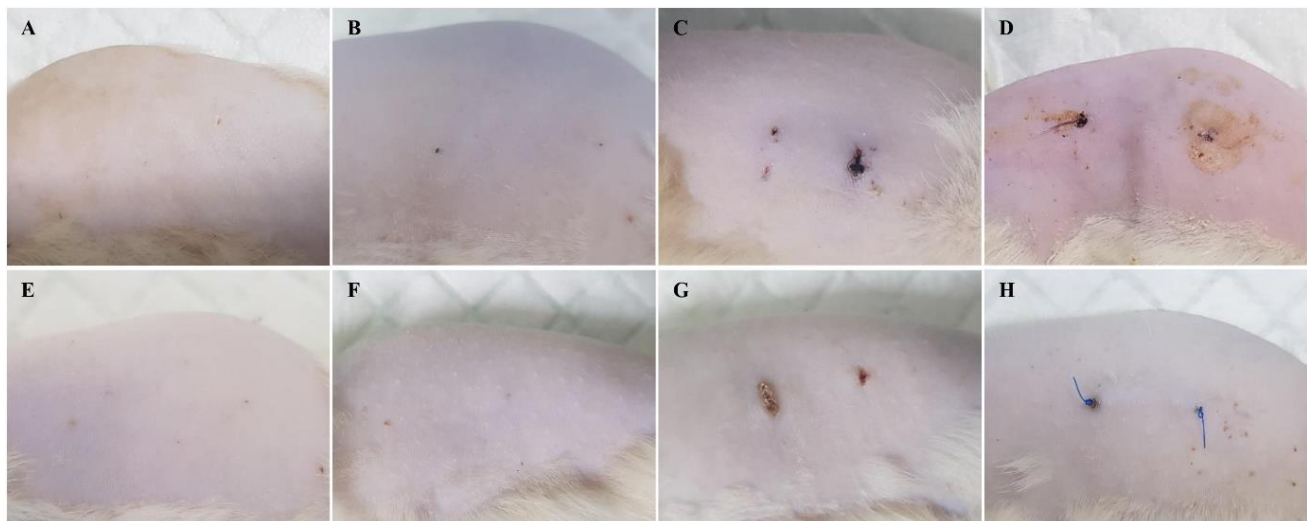


Figure 1. The macroscopy of 11-12-month-old Sprague-Dawley rats' skin after suture implant on days three and seven. **A:** Skin of P1 group on day 3; **B:** Skin of P2 group on day 3 after stabbed using cannula; **C:** Skin of P3 group on day 3 after suture implant using polydioxanone; **D:** Skin of P4 group on day 3 after suture implant using polydioxanone coated with calabash fruit extract; **E:** Skin of P1 group on day 7; **F:** Skin of P2 group on day 7 after stabbed using cannula; **G:** Skin of P3 group after 7 days of suture implant using polydioxanone; **H:** Skin of P4 group after suture implant using PDO coated with calabash fruit extract.

Histopathological examination confirmed the macroscopic lesions. The analysis showed that the suture implant leads to intradermal wounds with varying diameters. The diameter of these intradermal wounds in P3 and P4 remained consistent from day 3 to day 7 due to the presence of the suture within the skin. Following this, inflammatory cell infiltration and fibrogenesis were observed. Notably, inflammation in group P4 decreased after day 7, accompanied by an increase in fibrogenesis compared to P3 ($p < 0.05$). The scores for neovascularization and the area of adipocytes in P3 and P4 differ significantly ($p > 0.05$). Finally, skin thickness in P3 and P4 was more significant than in P1 and P2 ($p < 0.05$; Table 2, Figure 2). After the administration of the suture implant, the thickness of the collagen bundles and collagen density significantly increased in group P4 on day 7 compared to the other groups ($p < 0.05$, Figure 3), indicating a denser collagen structure.

The immunohistochemical analysis revealed that the suture implant leads to increased levels of IL-6 and FGF, which started on day 3 and were significantly higher on day 7 than in the control group ($p < 0.05$). The most significant increases in IL-6 and FGF were observed in group P4 throughout the observation period ($p < 0.05$; Figure 4).

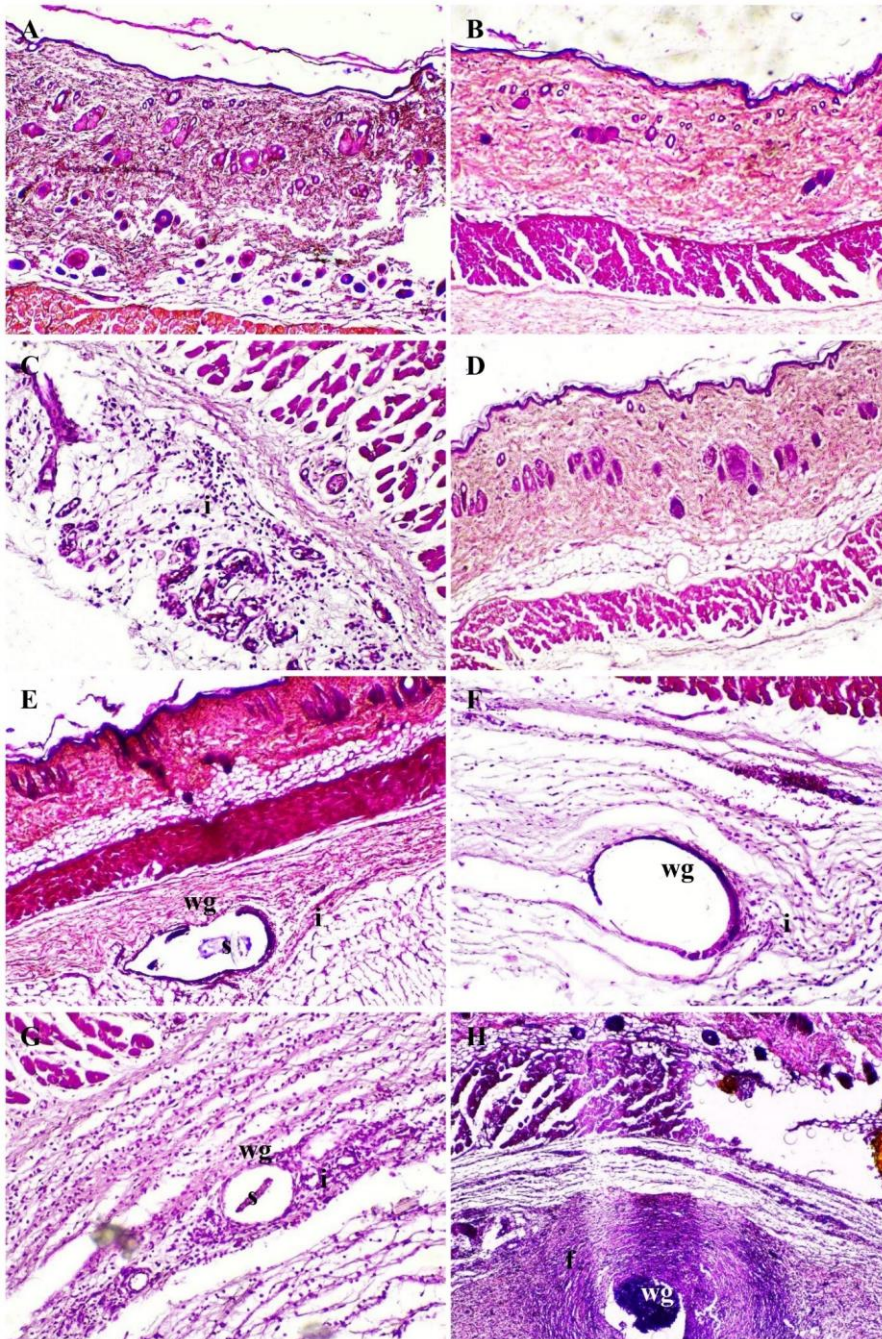


Figure 2. The histopathology of 11-12-month-old Sprague-Dawley rats' skin after suture implant on days three and seven. **A:** Skin of P1 group on days 3 indicating typical histology; **B:** Skin of P1 group on days 7 indicating typical histology; **C:** Skin of P2 group on day 3 indicating mild inflammation (i) on the dermal part; **D:** Skin of P2 group indicating the repair after inflammation on day 7 after stabbed using cannula; **E:** Skin of P3 group indicating the wound gap (WG) and moderate inflammation (i) was observed on day 3 after PDO implant on the dermal part; **F:** Skin of P3 group on day 7 indicating the wound gap (wg) become wider, with mild inflammation (i); **G:** Skin of P4 group indicating the suture (s) surrounded by wound gap (wg) with moderate inflammation (i) on day 3; **H:** Skin of P4 group indicating the fibrogenesis (f) become denser on day 7 surrounding wound gap (wg) on day 7. (H&E, 100 \times , A-H).

Table 2. The histopathology of 11-12-month-old Sprague-Dawley rats' skin after suture implant on days three and seven

Parameter	Day	Group			
		P1	P2	P3	P4
Intradermal wound Diameter (μm)	3	0.00 ± 0.00^a	0.00 ± 0.00^a	14.75 ± 3.04^b	16.53 ± 2.04^b
	7	0.00 ± 0.00^a	0.00 ± 0.00^a	17.65 ± 2.78^b	16.77 ± 2.76^b
Score of inflammatory cells (sel)	3	0.00 ± 0.00^a	1.25 ± 0.50^b	2.50 ± 0.57^c	2.50 ± 0.57^c
	7	0.00 ± 0.00^a	0.00 ± 0.00^a	2.25 ± 0.50^b	1.75 ± 0.50^b
Score of fibroblasts (sel)	3	22.00 ± 7.52^a	18.25 ± 1.89^a	57.50 ± 11.09^b	91.25 ± 7.93^c
	7	22.75 ± 6.13^a	15.50 ± 1.29^a	152.00 ± 10.47^b	260.25 ± 31.51^c
Neovascularization (%)	3	0.50 ± 0.57^a	0.75 ± 0.50^a	1.75 ± 0.50^b	2.00 ± 0.81^b
	7	0.50 ± 0.57^a	0.50 ± 0.57^a	2.50 ± 0.57^b	2.50 ± 0.57^b
Area of adipocyte (μm^2)	3	1945.36 ± 249.34^a	2058.35 ± 158.49^b	1377.05 ± 17.29^c	1650.42 ± 25.35^d
	7	1969.83 ± 116.29^a	1921.14 ± 337.73^a	1729.50 ± 31.63^b	$1629.91 \pm 28.90^{a,b}$
Skin thickness (μm)	3	1188.50 ± 49.18^a	1238.50 ± 22.15^a	1434.25 ± 59.73^b	1433.25 ± 10.50^b
	7	1225.00 ± 27.36^a	1236.00 ± 6.37^a	1522.75 ± 12.84^b	1650.00 ± 67.01^b

P1: Control with normal skin; P2: Skin stabbed using a cannula; P3: Skin implanted with polydioxanone; P4: Skin implanted with polydioxanone coated with Calabash fruit extract. ^{a,b,c} Different superscript letters indicated significant differences in each row ($p < 0.05$).

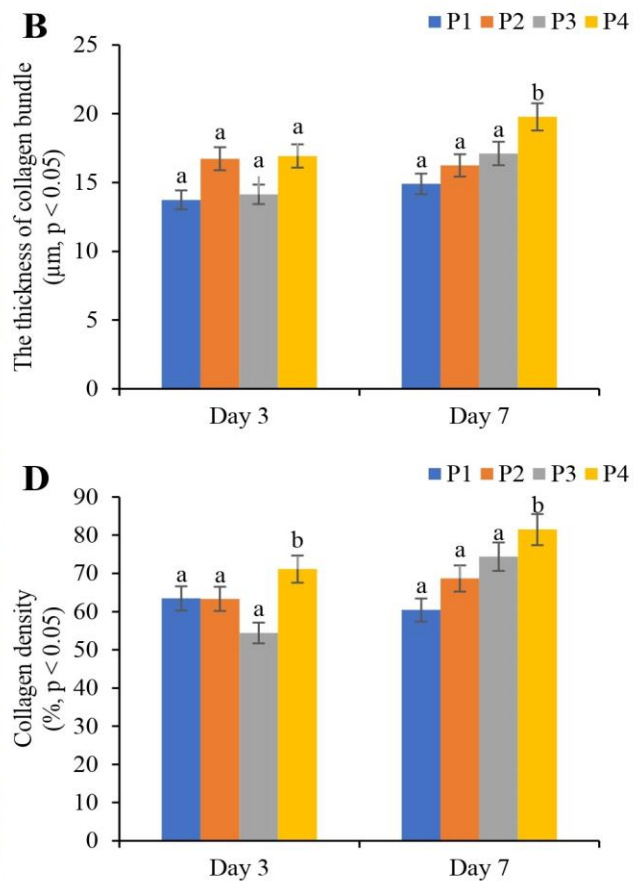
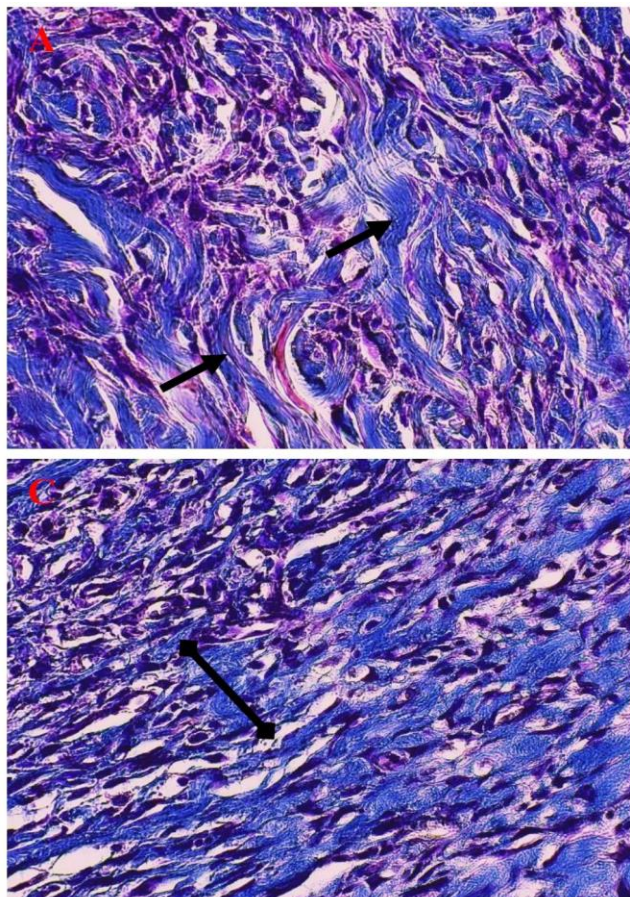


Figure 3. Collagenization of 11-12-month-old Sprague-Dawley rats' skin after suture implant on days three and seven. **A:** Collagen bundle of skin, which is measured; **B:** Thickness of collagen bundle on day 3 and 7 after suture implant; **C:** Collagen density of skin; **D:** Collagen density of skin on day 3 and 7 after suture implant (Mallory staining, 400 \times , A, C).

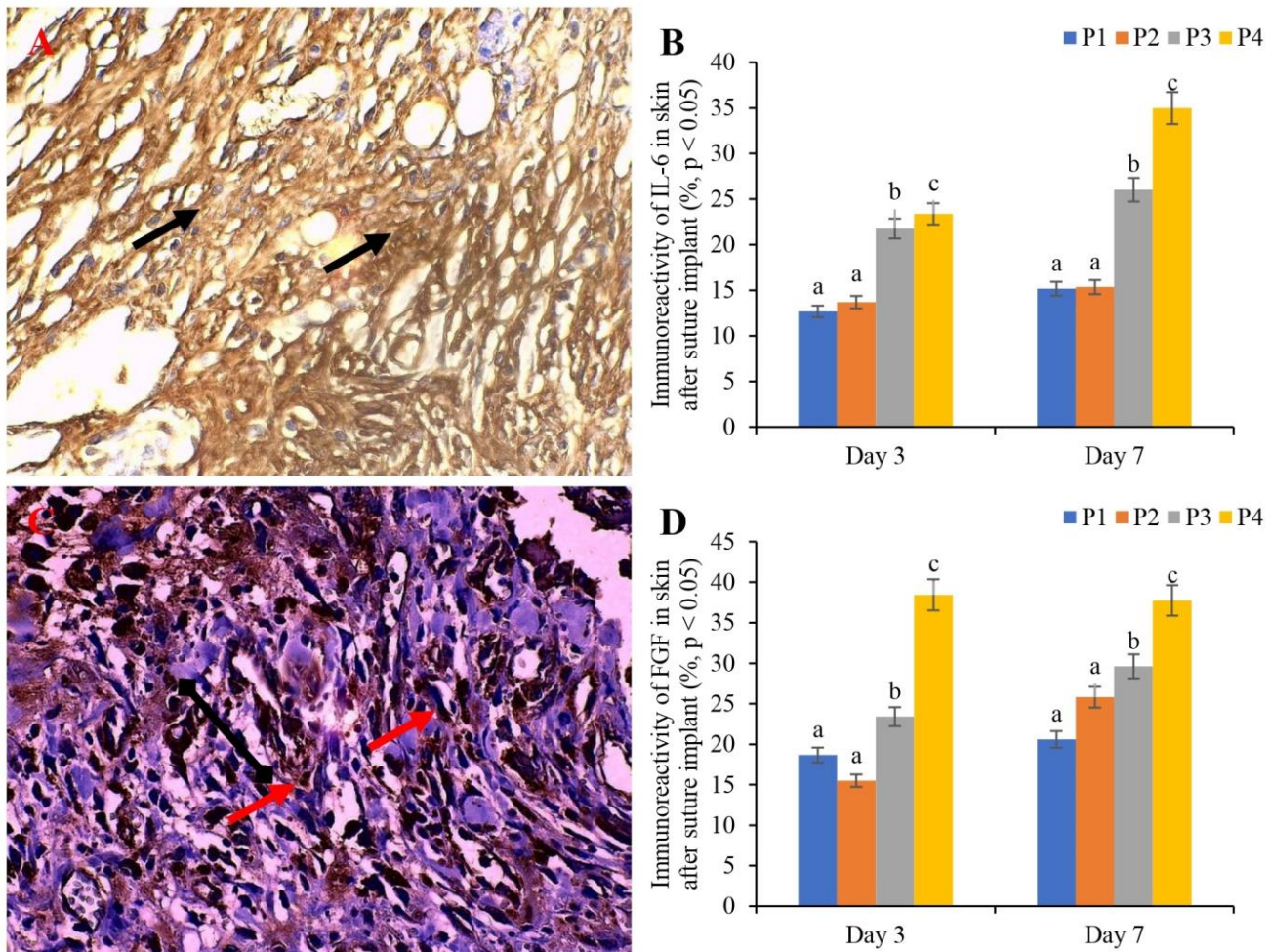


Figure 4. Immunoreactivity of IL-6 and FGF 11-12-month-old Sprague-Dawley rats' skin after suture implant on days three and seven. **A:** Immunoreactivity of IL-6 (arrow) of skin after suture implant; **B:** Percentage of immunoreactivity of IL-6 on day 3 and 7 after suture implant; **C:** Immunoreactivity of FGF (arrow) of skin after suture implant; **D:** Percentage of immunoreactivity of FGF on day 3 and 7 after suture implant.

DISCUSSION

Suture implants are aesthetic procedures designed to enhance skin tensile strength and elasticity (Stoecker et al., 2018). The skin's elasticity is influenced by collagen density within the dermal layer, which is stimulated by collagenization through the FGF pathway (Farooq et al., 2021). The present study demonstrated that collagenization can be enhanced by using suture implants made from PDO (polydioxanone). Polydioxanone is widely used in aesthetic procedures because it is readily available on the market and is absorbable by the body (Ahn and Choi, 2019).

In this study, using PDO as a suture implant material promoted fibrogenesis, neovascularization, the area of adipocytes, skin thickness, collagenization, and immunoreactivity of IL-6 and FGF in the dermal layer. However, this was accompanied by a large area of intradermal wounds and moderate inflammation. These findings align with Ernanda et al. (2024), who noted that PDO threads can lead to significant tissue lesions and inflammatory responses within three days of implantation. Additionally, Li et al. (2023) reported that PDO has advantages such as biocompatibility, mechanical stability, and degradation, but can also cause mild to moderate inflammatory responses. These disadvantages may be reduced by using a coating material with antioxidant-rich compounds or ascorbic acid on the sutures (Mangir et al., 2016).

The present study utilized CFE containing various biochemical compounds, including ascorbic acid, flavonoids, alkaloids, tannins, saponins, and phenolics. Bechara et al. (2022) stated that ascorbic acid is a beneficial antioxidant that can reduce local inflammation. It decreases the levels of reactive oxygen species (ROS) in adipose tissue, improves oxidative balance, and promotes the proliferation and integrity of adipocytes (Wang et al., 2022). Furthermore, a shorter inflammatory period enhances neovascularization and fibrogenesis. Mohammed et al. (2015) found that adequate amounts of ascorbic acid can increase fibrogenesis, extracellular matrix deposition, and neovascularization during wound healing. The study by Mohammed et al. (2015) aligns with the present study, which showed that group P4 exhibited mild inflammation alongside high levels of neovascularization, fibrogenesis, and minimal intradermal wound area.

The combination of PDO coated with CFE represents a novel model for suture implants. The increase in fibroblast cell numbers was directly proportional to the rise in collagen bundle thickness and density in the P4 group compared to other treatment groups. Fibroblasts are the most abundant cells in connective tissues, responsible for synthesizing

extracellular matrix components, including fibres and ground substances (Rahajeng *et al.*, 2023). Connective tissue fibres consist of collagen, reticular, and elastic fibres (Baumann *et al.*, 2021). Ascorbic acid is crucial in promoting fibroblast cell proliferation and is an essential cofactor for lysyl and prolyl hydroxylase, two vital enzymes in collagen biosynthesis (Lima *et al.*, 2009). Ascorbic acid is necessary for activating the enzyme prolyl hydroxylase, which converts proline residues in collagen into hydroxyproline (Chugaeva *et al.*, 2023). Without hydroxyproline, collagen polypeptides cannot properly form the triple helix structure required for physiological conditions, producing inadequate collagen fibre (Cao *et al.*, 2022). Increased collagen density increases tissue strength and accelerates healing (Rahajeng *et al.*, 2023).

Collagen production is influenced by various factors, including chemokines, cytokines, growth factors (such as transforming growth factor- β , TGF- β), and VEGF (Chaitrakoonthong *et al.*, 2020). One critical interleukin involved in fibrogenesis is IL-6. Interleukin-6 is a pro-inflammatory cytokine that changes expression in response to external stimuli and is crucial for promoting tissue regeneration and collagen matrix remodeling (Ernanda *et al.*, 2024). Interleukin-6 is essential in acute inflammation and is necessary for effective wound healing. Prolonged elevations of IL-6 can lead to delayed wound healing (Johnson *et al.*, 2020). Fibroblast growth factor is a growth factor that significantly impacts tissue fixation and regeneration (Ganesha *et al.*, 2019) and is vital for wound healing by stimulating fibroblast proliferation, inducing neovascularization, and increasing collagen synthesis (Matsumoto *et al.*, 2013).

The use of CFE as a coating for suture implants reduces the expression of pro-inflammatory factors while enhancing the expression of wound-healing factors. Thus, it plays a crucial role in all three phases of wound healing, including inflammation, proliferation, and regeneration (Nasab *et al.*, 2023).

CONCLUSION

This study showed that 100% CFE can improve skin quality after suture implantation. The significant positive effects of CFE on skin histopathology, collagen formation, and the immunoreactivity of IL-6 and FGF suggest its potential for applications in wound healing. However, further research with a large number of samples is needed to investigate other beneficial effects and potential toxicity in cosmetic uses to ensure the safety of using CFE as a coating material for suture implants.

DECLARATIONS

Acknowledgments

The authors acknowledge the Department of Pharmacology, Faculty of Veterinary Medicine, University of Wijaya Kusuma Surabaya, Indonesia, for supporting and providing the research funding. Moreover, the authors acknowledge the Department of Pathology, Faculty of Veterinary Medicine, Universitas Gadjah Mada, Indonesia, for supporting the histopathology analysis.

Authors' contributions

Yos Adi Prakoso and Sitarina Widyarini supervised, investigated, and designed the study. Ria Utami and Yos Adi Prakoso performed the study, collected the data, analyzed the data, and prepared the draft of the manuscript. Sitarina Widyarini, Bambang Sutrisno, and Micco Joshua Apriano Pangaribuan edited and corrected the manuscript before submission. Yos Adi Prakoso and Ria Utami revised the manuscript after corrections from the reviewer. All authors have read and approved the final version of the manuscript before publication in the present journal.

Funding

This study was funded by Farmart through the Internal Hibah from the Department of Pharmacology, UWKS.

Competing interests

The authors have no conflicts of interest.

Ethical considerations

All authors contributed to the preparation of this original article, and it was originally written and has not been published elsewhere by the authors.

Availability of data and materials

The data to support this study's findings is available upon reasonable request to the corresponding author.

REFERENCES

- Ahn SK and Choi HJ (2019). Complication after PDO threads lift. *The Journal of Craniofacial Surgery*, 30(5): e467-e469. DOI: <https://www.doi.org/10.1097/scs.0000000000005644>
- Ajuru MG, Williams LF, and Ajuru G (2017). Qualitative and quantitative phytochemical screening of some plants used in ethnomedicine in the Niger delta region of Nigeria. *Journal of Food and Nutrition Sciences*, 5(5): 198-205. DOI: <https://www.doi.org/10.11648/j.fjns.20170505.16>

- Antar SA, Ashour NA, Marawan ME, and Al-Karmalawy AA (2023). Fibrosis: Types, effects, markers, mechanisms for disease progression, and its relation with oxidative stress, immunity, and inflammation. *International Journal of Molecular Sciences*, 24(4): 4004. DOI: <https://www.doi.org/10.3390/ijms24044004>
- Baumann L, Bernstein EF, Weiss AS, Bates D, Humphrey S, Silberberg M, and Daniels R (2021). Clinical relevance of elastin in the structure and function of skin. *Aesthetic Surgery Journal Open Forum*, 3(3): ojab019. DOI: <https://www.doi.org/10.1093/asjof/ojab019>
- Bechara N, Flood VM, and Gunton JE (2022). A systematic review on the role of vitamin C in tissue healing. *Antioxidants*, 11(8): 1605. DOI: <https://www.doi.org/10.3390/antiox11081605>
- Bonifant H and Holloway S (2019). A review of the effects of ageing on skin integrity and wound healing. *British Journal of Community Nursing*, 24(Sup3): S28-S33. DOI: <https://www.doi.org/10.12968/bjcn.2019.24.Sup3.S28>
- Borrelli MR (2018). What is the role of plastic surgery in global health? A review. *World Journal of Plastic Surgery*, 7(3): 275-282. DOI: <https://www.doi.org/10.29252/wjps.7.3.275>
- Cao S, Xiao Y, Huang R, Zhao D, Xu W, Li S, Tang J, Qu F, Jin J, Xie S et al. (2022). Dietary supplementation with hydroxyproline enhances growth performance, collagen synthesis and muscle quality of *Carassius auratus* triploid. *Frontiers in Physiology*, 13: 913800. DOI: <https://www.doi.org/10.3389/fphys.2022.913800>
- Castro JRD, Pereira FDS, Chen L, Arana-Chavez VE, Ballester RY, DiPietro LA, and Simões A (2020). Improvement of full-thickness rat skin wounds by photobiomodulation therapy (PBMt): A dosimetric study. *Journal of Photochemistry and Photobiology*, 206: 111850. DOI: <https://www.doi.org/10.1016/j.jphotobiol.2020.111850>
- Chaitrakoonthong T, Ampornaramveth R, and Kamolratanakul P (2020). Rinsing with L-ascorbic acid exhibits concentration-dependent effects on human gingival fibroblast *in vitro* wound healing behavior. *International Journal of Dentistry*, 2020: 4706418. DOI: <https://www.doi.org/10.1155/2020/4706418>
- Chugaeva UY, Raouf M, Morozova NS, and Mahdavian L (2023). Effects of L-ascorbic acid (C₆H₈O₆: Vit-C) on collagen amino acids: DFT study. *Amino Acids*, 55(11): 1655-1664. DOI: <https://www.doi.org/10.1007/s00726-023-03339-5>
- Donalisio M, Rittà M, Francese R, Civra A, Tonetto P, Coscia A, Giribaldi M, Cavallarin L, Moro GE, Bertino E et al. (2018). High temperature-short time pasteurization has a lower impact on the antiviral properties of human milk than holder pasteurization. *Frontiers in Pediatrics*, 6: 304. DOI: <https://www.doi.org/10.3389/fped.2018.00304>
- Duan L and Yu X (2023). Fibroblasts: New players in the central nervous system?. *Fundamental Research*, 4(2): 262-266. DOI: <https://www.doi.org/10.1016/j.fmre.2023.01.014>
- Edwards JV, Prevost NT, Yager D, Mackin R, Santiago M, Chang S, Condon B, and Dacorta J (2022). Ascorbic acid as an adjuvant to unbleached cotton promotes antimicrobial activity in spunlace nonwovens. *International Journal of Molecular Sciences*, 23(7): 3598. DOI: <https://www.doi.org/10.3390/ijms23073598>
- Ernanda MH, Damayanti NA, and Sari W (2024). Effects of suture implantation using different suture materials on the skin histopathology, immune expression of interleukin-6, and hematological parameters in rat. *World's Veterinary Journal*, 14(1): 97-103. DOI: <https://www.doi.org/10.54203/scil.2023.wvj13>
- Farooq M, Khan AW, Kim MS, and Choi S (2021). The role of fibroblast growth factor (FGF) signaling in tissue repair and regeneration. *Cells*, 10(11): 3242. DOI: <https://www.doi.org/10.3390/cells10113242>
- Feldman AT and Wolfe D (2014). Tissue processing and hematoxylin and eosin staining. In: C. Day (Editor), *Histopathology. Methods in molecular biology*. Humana Press., New York, NY, pp. 31-43. DOI: https://www.doi.org/10.1007/978-1-4939-1050-2_3
- Ganesha R, Hernawan I, Hendarti HT, Radithia D, Hadi P, Ayuningtyas NF, and Ernawati DS (2019). Expression of FGF-2 and fibronectin in citrus limon fruit peel malang essential oil gel treated traumatic ulcer in diabetic Wistar rats (*Rattus norvegicus*). *Research Journal of Pharmacy and Technology*, 12(7): 3350-3354. DOI: <http://www.doi.org/10.5958/0974-360X.2019.00565.1>
- Gromkowska-Kepka KJ, Puścion-Jakubik A, Markiewicz-Żukowska R, and Socha K (2021). The impact of ultraviolet radiation on skin photoaging - review of *in vitro* studies. *Journal of Cosmetic Dermatology*, 20(11): 3427-3431. DOI: <https://www.doi.org/10.1111/jocd.14033>
- He P, Liu Z, Chen H, Huang G, Mao W, and Li A (2023). The role of triclosan-coated suture in preventing surgical infection: A meta-analysis. *Joint Diseases and Related Surgery*, 34(1): 42-49. DOI: <https://www.doi.org/10.52312/jdrs.2023.842>
- Hidayah JH, Prakoso YA, and Widayari S (2023). Brain histopathological changes after treatment using calabash fruit (*Crescentia cujete* L.) in rat model with artificially induced ischemic stroke. *Advances in Animal and Veterinary Sciences*, 11(12): 2003-2009. DOI: <http://www.doi.org/10.17582/journal.aavs/2023/11.12.2003.2009>
- Johnson BZ, Stevenson AW, Prêle CM, Fear MW, and Wood FM (2020). The role of IL-6 in skin fibrosis and cutaneous wound healing. *Biomedicine*, 8(5): 101. DOI: <https://www.doi.org/10.3390/biomedicine8050101>
- Li Z, Kong P, Liu X, Feng S, Ouyang W, Wang S, Hu X, Xie Y, Zhang F, Zhang Y et al. (2023). A fully biodegradable polydioxanone occluder for ventricle septal defect closure. *Bioactive Materials*, 24: 252-262. DOI: <https://www.doi.org/10.1016/j.bioactmat.2022.12.018>
- Lima CC, Pereira AP, Silva JR, Oliveira LS, Resck MC, Grechi CO, Bernardes MT, Olímpio FM, Santos AM, Incerpi EK et al. (2009). Ascorbic acid for the healing of skin wounds in rats. *Brazilian Journal of Biology*, 69(4): 1195-1201. DOI: <https://www.doi.org/10.1590/s1519-69842009000500026>
- Mangir N, Bullock AJ, Roman S, Osman N, Chapple C, and MacNeil S (2016). Production of ascorbic acid releasing biomaterials for pelvic floor repair. *Acta Biomaterialia*, 29: 188-197. DOI: <https://www.doi.org/10.1016/j.actbio.2015.10.019>
- Matsumoto S, Tanaka R, Okada K, Arita K, Hyakusoku H, Miyamoto M, Tabata Y, and Mizuno H (2013). The effect of control-released basic fibroblast growth factor in wound healing: Histological analyses and clinical application. *Plastic and Reconstructive Surgery Global Open*, 1(6): e44. DOI: <https://www.doi.org/10.1097/GOX.0b013e3182a88787>
- Mohammed BM, Fisher BJ, Kraskauskas D, Ward S, Wayne JS, Brophy DF, Fowler AA, Yager DR, and Natarajan R (2015). Vitamin C promotes wound healing through novel pleiotropic mechanisms. *International Wound Journal*, 13(4): 572-84. DOI: <https://www.doi.org/10.1111/iwj.12484>
- Nasab MG, Bakhshayesh ARD, Gharalari NA, and Mehdipour A (2023). Biomolecular and cellular effects in skin wound healing: The association between ascorbic acid and hypoxia-induced factor. *Journal of Biological Engineering*, 17: 62. Available at: <https://link.springer.com/article/10.1186/s13036-023-00380-6>
- Parvin MS, Das N, Jahan N, Akhter MA, Nahar L, and Islam ME (2015). Evaluation of *in vitro* anti-inflammatory and antibacterial potential of *Crescentia cujete* leaves and stem bark. *BMC Research Notes*, 8: 412. DOI: <https://www.doi.org/10.1186/s13104-015-1384-5>
- Plavec T, Švara T, Zdovc I, Gombač M, Damjanovska M, Stopar Pintarič T, Cvetko E, and Seliškar A (2020). Clinical and histologic tissue responses of skin incisions closed with glycomer 631 and lactomer 9-1 using a subcuticular technique in pigs. *BMC Veterinary Research*, 16(1): 87. DOI: <https://www.doi.org/10.1186/s12917-020-02290-x>
- Prakoso YA, Hidayah N, Rini CS, and Kurniasih K (2021). Dynamic change of blood profile in rat models with acute skin injury artificially infected with methicillin-resistant *Staphylococcus aureus*. *Veterinary World*, 14(8): 2085-2090. DOI: <http://www.doi.org/10.14202/vetworld.2021.2085-2090>

- Prakoso YA, Rini CS, Rahayu A, Sigit M, and Widhowati D (2020). Celery (*Apium graveolens*) as a potential antibacterial agent and its effect on cytokeratin-17 and other healing promoters in skin wounds infected with methicillin-resistant *Staphylococcus aureus*. *Veterinary World*, 13(5): 865-871. DOI: <http://www.doi.org/10.14202/vetworld.2020.865-871>
- Prakoso YA, Susilo A, and Widyarini S (2024). The standardization and efficacy of fermented *Crescentia cujete* (L.) in combination with enrofloxacin against artificially induced pneumonic pasteurellosis in rat models. *Open Veterinary Journal*, 14(12): 3404-3416. DOI: <https://www.doi.org/10.5455/OVJ.2024.v14.i12.25>
- Prudovsky I (2021). Cellular mechanisms of FGF-stimulated tissue repair. *Cells*, 10(7): 1830. DOI: <https://www.doi.org/10.3390/cells10071830>
- Rahajeng, Nurseta T, Mustofa E, Irwanto Y, Pamungkas AFU, Harnandari DEP, and Herliawati PA (2023). Effect of vitamin C exposure to fibroblast cells on woman uterosacral ligament culture. *Medical Laboratory Technology Journal*, 9(2): 133-141. DOI: <https://www.doi.org/10.31964/mltj.v9i2.521>
- Rebuelto M, Ambros L, Montoya L, and Bonafine R (2002). Treatment-time-dependent difference of ketamine pharmacological response and toxicity in rats. *Chronobiology International*, 19(5): 937-945. DOI: <https://www.doi.org/10.1081/cbi-120014572>
- Sagrin MS, Lasano NF, Shukri R, and Ramli NS (2019). Antioxidant properties and toxicity assessment of the *Crescentia cujete* extracts in brine shrimp (*Artemia salina*). *Sains Malaysiana*, 48(4): 831-940. DOI: <http://www.doi.org/10.17576/jsm-2019-4804-15>
- Selvi F, Cakarar S, Can T, Kirli Topcu Sİ, Palancioglu A, Keskin B, Bilgic B, Yaltirik M, and Keskin C (2016). Effects of different suture materials on tissue healing. *Journal of Istanbul University Faculty of Dentistry*, 50(1): 35-42. DOI: <https://www.doi.org/10.17096/jiufd.79438>
- Sotoudeh N and Namavar MR (2022). Optimisation of ketamine-xylazine anaesthetic dose and its association with changes in the dendritic spine of CA1 hippocampus in the young and old male and female Wistar rats. *Veterinary Medicine and Science*, 8(6): 2545-2552. DOI: <https://www.doi.org/10.1002/vms3.936>
- Sprowson AP, Jensen C, Parsons N, Partington P, Emmerson K, Carluke I, Asaad S, Pratt R, Muller S, Ahmed I et al. (2018). The effect of triclosan-coated sutures on the rate of surgical site infection after hip and knee arthroplasty: a double-blind randomized controlled trial of 2546 patients. *The Bone and Joint Journal*, 100-B(3): 296-302. DOI: <https://www.doi.org/10.1302/0301-620X.100B3.BJJ-2017-0247.R1>
- Stoecker A, Howerter S, Young J, and Lear W (2018). The use of a suture retention device with punctureless technique for rapid tissue expansion in facial and lower extremity wounds. *Journal of The American Academy of Dermatology Case Reports*, 4(9): 910-914. DOI: <https://www.doi.org/10.1016/j.jdcrr.2018.09.005>
- Villarreal-González RV, González-Díaz S, Vidal-Gutiérrez O, de la Cruz-de la Cruz C, Pérez-Ibave DC, and Garza-Rodríguez ML (2024). Interleukin-6 as a biomarker of hypersensitivity reactions in chemotherapeutics and monoclonal antibodies. *Journal of Oncology Pharmacy Practice*, 30(8): 1294-1301. DOI: <https://www.doi.org/10.1177/10781552231204367>
- Wang X, Xu M, and Li Y (2022). Adipose tissue aging and metabolic disorder, and the impact of nutritional interventions. *Nutrients*, 14(15): 3134. DOI: <https://www.doi.org/10.3390/nu14153134>
- Wilson H, Avsar P, Patton D, Budri AMV, and Moore Z (2023). Skin hydration measurement and the prediction of the early development of pressure ulcers among at risk adults: A systematic review. *International Wound Journal*, 20(3): 880-891. DOI: <https://www.doi.org/10.1111/iwj.13934>
- Wilujeng S, Wirdjaatmadja R, and Prakoso YA (2022). Effects of extraction, fermentation, and storage processes on the levels of choline derived from calabash fruit (*Crescentia cujete* L.). *Journal of Research in Pharmacy*, 27(2): 620-626. DOI: <http://www.doi.org/10.29228/jrp.344>
- Wongkar FL, Prakoso YA, and Wijayanti AD (2024). Effects of *Crescentia cujete* (L.) fruit extract on the profile of hematology of ranchu goldfish (*Carassius auratus*). *Open Veterinary Journal*, 14(11): 3017-3025. DOI: <https://www.doi.org/10.5455/OVJ.2024.v14.i11.30>
- Ye Y, Jia R, Tang L, and Chen F (2014). *In vivo* antioxidant and anti-skin-aging activities of ethyl acetate extraction from *Idesia Polycarpa* defatted fruit residue in aging mice induced by D-galactose. *Evidence-Based Complementary and Alternative Medicine*, 2014: 185716. DOI: <https://www.doi.org/10.1155/2014/185716>

Publisher's note: Scienceline Publication Ltd. remains neutral with regard to jurisdictional claims in published maps and institutional affiliations.



Open Access: This article is licensed under a Creative Commons Attribution 4.0 International License, which permits use, sharing, adaptation, distribution and reproduction in any medium or format, as long as you give appropriate credit to the original author(s) and the source, provide a link to the Creative Commons licence, and indicate if changes were made. The images or other third party material in this article are included in the article's Creative Commons licence, unless indicated otherwise in a credit line to the material. If material is not included in the article's Creative Commons licence and your intended use is not permitted by statutory regulation or exceeds the permitted use, you will need to obtain permission directly from the copyright holder. To view a copy of this licence, visit <https://creativecommons.org/licenses/by/4.0/>.