



Morphological and Functional Characteristics of the Heart under Chronic Ischemic Injury Conditions Following the Use of Allogeneic Biomaterial in Rats

Lebedeva Anna¹ , Musina Lyalya¹ , Prusakov Alexey² , and Ponamarev Vladimir^{2*}

¹Federal State Budgetary Scientific Institution, All-Russian Research Veterinary Institute of Pathology, Pharmacology and Therapy, Ufa, Russia

²Federal State Budgetary Educational Institution of Higher Education, Saint Petersburg State University of Veterinary Medicine, Saint Petersburg, Russia

*Corresponding author's Email: psevdopyos@mail.ru; nir@spbguv.ru

ABSTRACT

One of the scientific approaches to correcting fibrotic myocardium is the development of regenerative medicine methods, which involve tissue therapy. The present study aimed to identify morphological and functional changes in the fibrous myocardium of rats after cryoinjury and the use of allogeneic biomaterial. The study included 80 Wistar rats divided into two groups, the control and the experimental group. All rats underwent a thoracotomy under general anesthesia with Xylazine and Zolazepam, and a section of the left ventricle was frozen with a cooled metal stylet. In the experimental group, a repeated thoracotomy was performed 45 days after cryodestruction. An allogeneic biomaterial suspension, dispersed from an acellular extracellular matrix with a particle size of 50 to 80 µm, was then injected intracardially into the area of cryogenic myocardial necrosis at a dose of 3 mg per animal. Forty-five days after the allogeneic biomaterial injection, the tolerance of rats to physical activity was assessed using the modified Porsolt test. After the tolerance test, the weight of the heart, the thickness of the left ventricular wall, the thickness of the scar, and the diameter of the damaged area were measured. Three myocardium samples were taken from each animal and processed for examination using a light microscope. Histological examination of the myocardium samples revealed an avascular scar. In the experimental group, the thickness of the muscular part was significantly higher than in the control group. Meanwhile, heart weight didn't differ much between the control and experimental group. The exercise tolerance of rats in the experimental group was higher than that of the control group and did not differ significantly from the intact values. The presented results supported the allogeneic biomaterial's positive influence on the rats' myocardium structure that had undergone cryogenic destruction.

Keywords: Allogeneic biomaterial, Chronic ischemic injury, Cryodestruction, Heart, Myocardium

INTRODUCTION

Even with advancements in diagnostic and treatment technologies such as CT scans, MRI, and ultrasound, chronic ischemic heart disease continues to be a major cause of cardiovascular disease and mortality globally (Fácil Rubio et al., 2024). Ischemic myocardial pathologies, such as Ischemic cardiomyopathy, myocardial infarction, and angina pectoris in animals, as in humans, are associated with insufficient blood supply to the heart muscle (Algoet et al., 2023). For pharmaco-correction of such conditions, Nitrates (Nitroglycerin) are used to dilate blood vessels and improve blood flow, beta-blockers (Atenolol) reduce heart rate and reduce the load on the heart, antiplatelet agents (Aspirin) and anticoagulants (Warfarin) prevent blood clots, and angiotensin-converting enzyme inhibitors (Enalapril) lower blood pressure and reduce the load on the heart (Chen et al., 2024). Despite significant breakthroughs in cardiology, the search for effective methods to restore cardiac function after ischemic injury remains an urgent task. About 5 to 15% of patients discharged from the hospital die within the first year; the subsequent annual mortality rate ranges from 2 to 5% (Baryshev et al., 2022; Kuznetsov et al., 2022; Alekhin et al., 2023). The high medical and social significance of myocardial infarction underscores the need for further improvement and development of effective and affordable treatment methods in the long-term management of the disease to prevent fibrotic degeneration of the myocardium, which impairs heart function (Garganeeva et al., 2015). One of the scientific approaches to correcting fibrotic myocardium can be the development of regenerative medicine methods, such as tissue therapy (Ponamarev et al., 2023a,b; Prusakova et al., 2023a,b). Recently, increasing attention has been paid to the use of biomaterials for regenerating damaged tissues. In particular, Allogeneic biomaterial (AB) represents a promising direction in cardiology due to its biocompatibility and potential to stimulate regenerative processes (Kruglyakov et al., 2004; Afanasiev et al., 2009; Garganeeva et al., 2015). The AB, derived from the acellular extracellular matrix, has proven to be a stimulator of organ and tissue regeneration, but it has not been previously used in cardiology (Muldashv et al., 2005).

ORIGINAL ARTICLE
Received: April 11, 2025
Revised: May 16, 2025
Accepted: June 10, 2025
Published: June 30, 2025

For different animal species, Cryoinjury is quite common. Frequent causes of such types of injuries are osmotic and thermal shock, cryoprotectant toxicity, and the growth of intracellular ice particles (Johnstone et al., 2023). Additionally, cryoinjury can serve as a model for other studies, such as those examining coronary artery stenosis (Maurya and Kumar, 2025). The present study aimed to identify morphological and functional changes in the fibrous myocardium of rats following cryoinjury and the use of AB, thereby providing a better understanding of the mechanisms of action of AB and their potential clinical applications in the treatment of ischemic heart disease.

MATERIALS AND METHODS

Ethical approval

The Ethics Committee of the Bashkir State Medical University (Ufa, Russia) approved the study. All manipulations were carried out in accordance with the provisions of the Order of the Ministry of Health of the Russian Federation dated April 1, 2016, No. 199n (On approval of the rules of good laboratory practice).

Study design

Eighty male Wistar rats, 2-3 months old and weighing from 200.0 and 250.0 g, were selected for the present study. Two groups were formed, consisting of a control group and an experimental group, each comprising 40 rats. The rats were housed in three cages (545 × 395 × 200 mm) with free access to water and food (Delta Feeds, BioPro, Novosibirsk, Russia).

Before the thoracotomy, rats were intramuscularly injected into the vastus femoris with Xylazine 2% (Interchemie, Netherlands) at a dose of 0.05 mg/kg, and after 10 minutes, Zoletil 50 (Virbac, France) at a dose of 0.5 mg/kg (Adamyan et al., 2011). The animal underwent a thoracotomy, the heart was removed, and a section of the left ventricle in the apex region was frozen with a six mm diameter metal stylet cooled in liquid nitrogen (Limited liability company, cryotrade engineering, Russia; Shutsky et al., 2019). The stylet was exposed to the heart for 10 seconds, after which the wound was sutured in layers (Shutsky et al., 2019). This method of cardiac cryodestruction enabled the standardization of myocardial damage in terms of volume and localization, making it convenient for the morphometric analysis of the damage zone. Pathological changes in the myocardium after cryodestruction are similar to those observed in coronary artery stenosis (Kruglyakov et al., 2004; Afanasiev et al., 2009).

During repeated thoracotomy, 45 days after cryodestruction in the experimental group, an AB suspension was injected into the area of cryogenic myocardial necrosis. The AB was diluted with 0.9% saline to obtain a suspension containing 0.5 mg of AB in 10 µl for each injection (Lebedeva et al., 2023). Each animal in the experimental group received six intramyocardial injections of AB suspension, three mg per animal in total, with one-day intervals in 10 days. The rats in the control group were injected with 0.9% saline solution at a dose of 10 µl per intramyocardial injection. The AB used in the present study was a dispersed form of acellular extracellular matrix with a particle size of 50 to 80 µm, developed at the Federal State Budgetary Institution (All-Russian Center for Eye and Plastic Surgery) of the Ministry of Health of the Russian Federation, Ufa, Russia. The biomaterial was manufactured in accordance with TS 42-2-537-87, certified, and approved for use in clinical practice by order of the government of the Russian Federation No. 857 dated June 13, 2020. For the present study, AB was made from rat tendons.

Forty-five days after the injection of AB and saline, all rats from both groups were tested for their tolerance to physical activity using a modified Porsolt test. During this test, rats were forced to swim with a load of 10% of their body weight until they became immobile (Karkishchenko et al., 2011). After the Porsolt test, all animals were euthanized with Xylazine 2% (Interchemie, Netherlands) at a dose of 0.15 mg/kg.

The heart weight was determined, and the thickness of the muscular part of the left ventricular wall, the thickness of the scar, and the diameter of the damaged area were measured on transverse sections of the rat's heart. Animal hearts were fixed for 36 hours in a 10% solution of neutral formaldehyde (Limited liability company formula, Russia), dehydrated in a series of alcohols; 70% ethanol for 3 to 5 minutes, 80% ethanol for 3 to 5 minutes, 95% ethanol for 3 to 5 minutes, 100% ethanol for 3 to 5 minutes, Xylene 1 for 3 to 5 minutes, Xylene 2 for 3 to 5 minutes, and embedded in paraffin (Yanin et al., 2015). Sections were cut on a LEICA RM 2145 microtome (G-M-I, Inc., Germany) and were stained with hematoxylin and eosin, according to van Gieson. The study and visualization of the preparations were carried out using a light microscope (Leica DMD 108, Germany) with specialized software for controlling settings and image capture.

Statistical analysis

The two-factor analysis of variance method was used. Data analysis was conducted using non-parametric (rank) methods, one-way analysis of variance according to the Kruskal-Wallis test, and comparison of uncorrelated data using the Mann-Whitney method. Medians (Me), variation limits (Min-Max), and standard score (Z) were used. The standard

score (Z) indicates the number of standard deviations between the value and the median. The diagram was constructed using the Statistical 6.0 program. In the present study, results were considered significant at $p < 0.05$.

RESULTS

Histological examination of the hearts 45 days after cryodestruction with liquid nitrogen revealed an avascular scar in the myocardium in the area of the left ventricle near the heart's apex in both groups. A network of collagen fibers developed in place of the damaged cardiomyocytes in all samples. Dense fibrous connective tissue was present in samples from both groups, characterized by a low degree of vascularization and a predominant content of fibroblastic cells, including fibroblasts, fibrocytes, and myofibroblasts (Figure 1).

At the stage of inclusion in the study, all rats were tested for exercise tolerance (Swimming) and demonstrated comparable results ($p < 0.05$). The duration of the exercise was 751 seconds (Minimum 589 seconds and maximum 783 seconds). In the control group, after 45 days, exercise tolerance decreased by 1.97 times compared with the intact rats ($p < 0.05$; Can et al., 2012). The exercise tolerance of rats in the experimental group was higher than that of the control group and did not differ significantly from the intact values ($p < 0.05$; Table 1; Can et al., 2012).

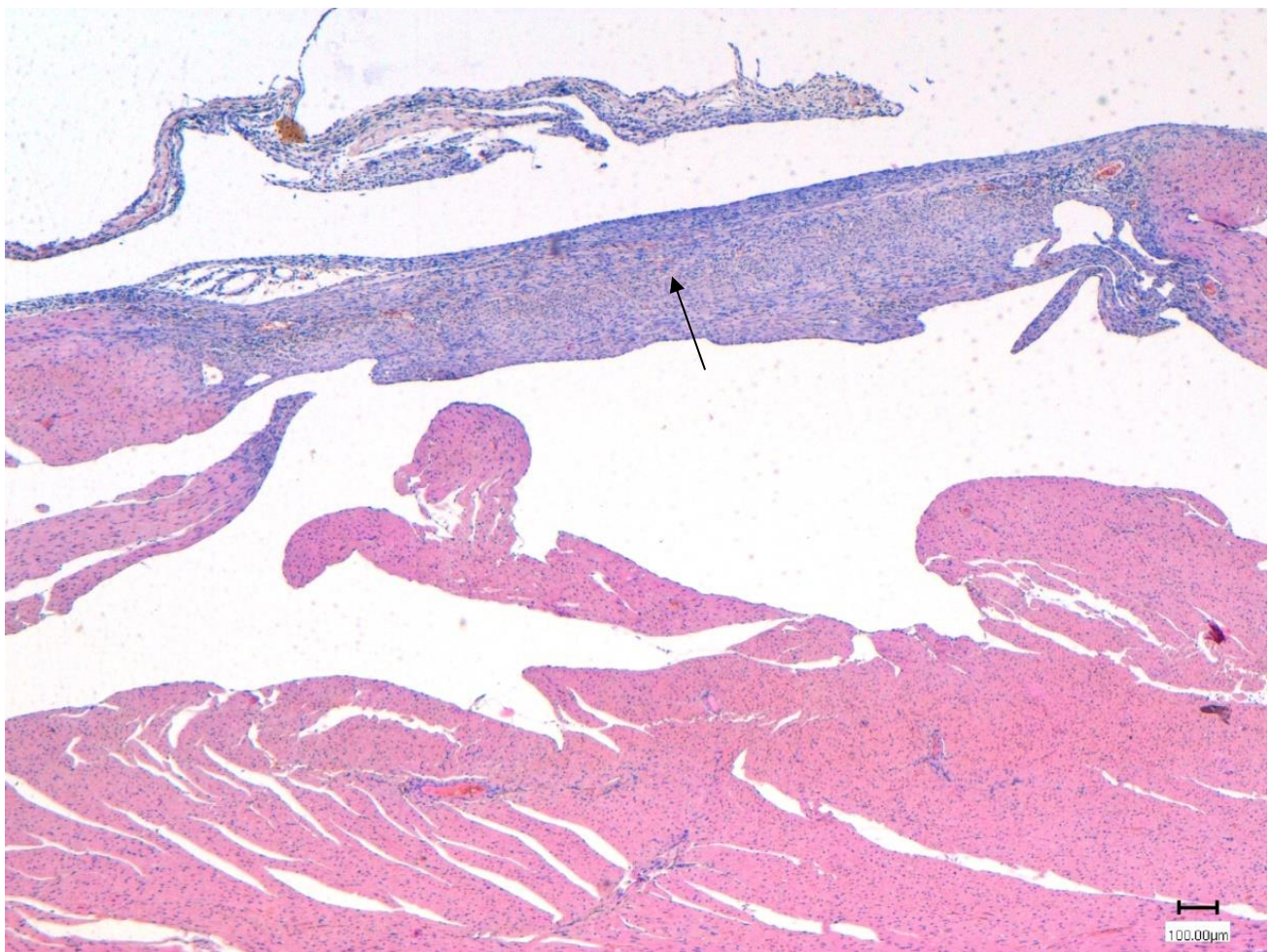


Figure 1. Fibrous degeneration of the rat's myocardium following destruction by liquid nitrogen after 45 days. A black arrow points out fibrous degeneration. H&E staining, X100.

Table 1. Influence of intramyocardial allogenic biomaterial injection on the swimming duration in rats following myocardial cryodestruction

Group	Swimming time (seconds)	Heart weight (g)
Control group	380 (min: 310, max: 403)	0.91* (min: 0.898, max: 0.916)
Experimental group	720* (min: 498, max: 751)	0.875 (min: 0.837, max: 0.943)

*: Significant difference in each column ($p < 0.05$)

The increase in the tolerant load in rats of the experimental group compared to the control group proved that the use of AB provided a functionally significant improvement in the condition of the heart muscle ($p < 0.05$). Given that the heart weights of both the control and experimental groups of rats were comparable, it can be considered that a reorganization of the scar and an enhancement in the metabolic condition of the myocardium, particularly as the exercise tolerance of the experimental group was superior to that of the control group and closely aligned with the values of intact rats ($p < 0.05$; [Can et al., 2012](#)). The increase in the modified Porsolt test duration in the experimental group compared to the control group corresponded with changes in myocardial structure; consequently, the hearts were examined morphologically.

Forty-five days after the administration of AB, the thickness of the muscular part of the left ventricle, the thickness of the scar, and the diameter of the damaged area were examined in all experimental rats. It turned out that in the experimental group (0.906 mm) after the administration of AB, the thickness of the muscular part of the left ventricle was significantly higher ($p < 0.05$, $Z = 2.6$) than in the control group (0.330 mm) due to the content of cardiac muscle fibers (Figure 2). Additionally, in the experimental group, accumulations of cardiomyocytes were found in the interfiber spaces of the previous cryogenic scar, forming clusters that could potentially create a functional syncytium.

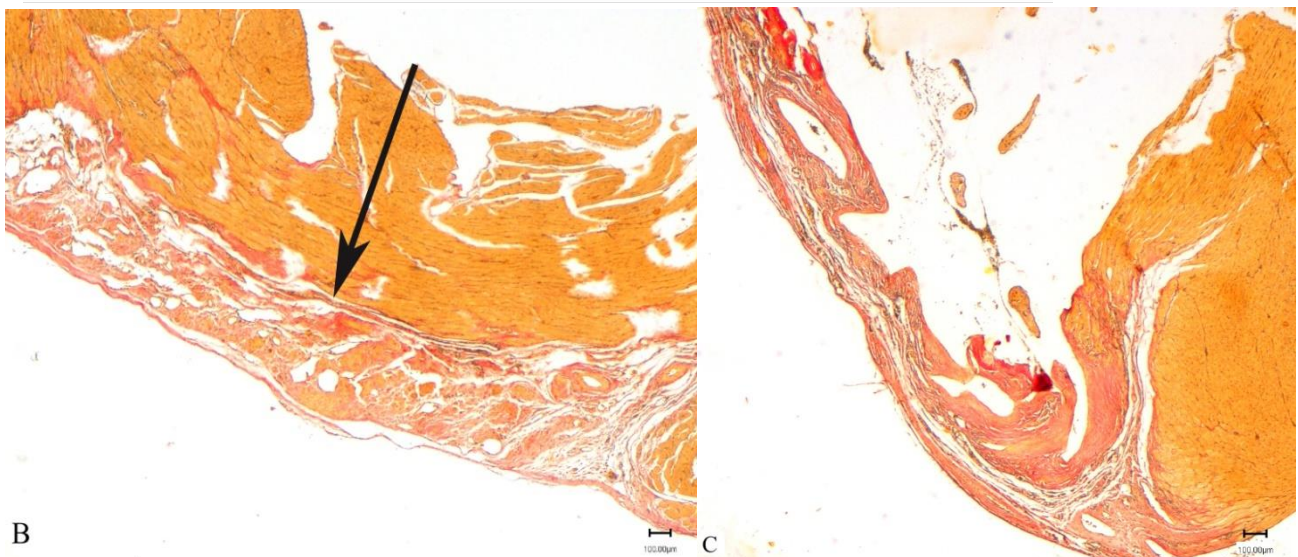
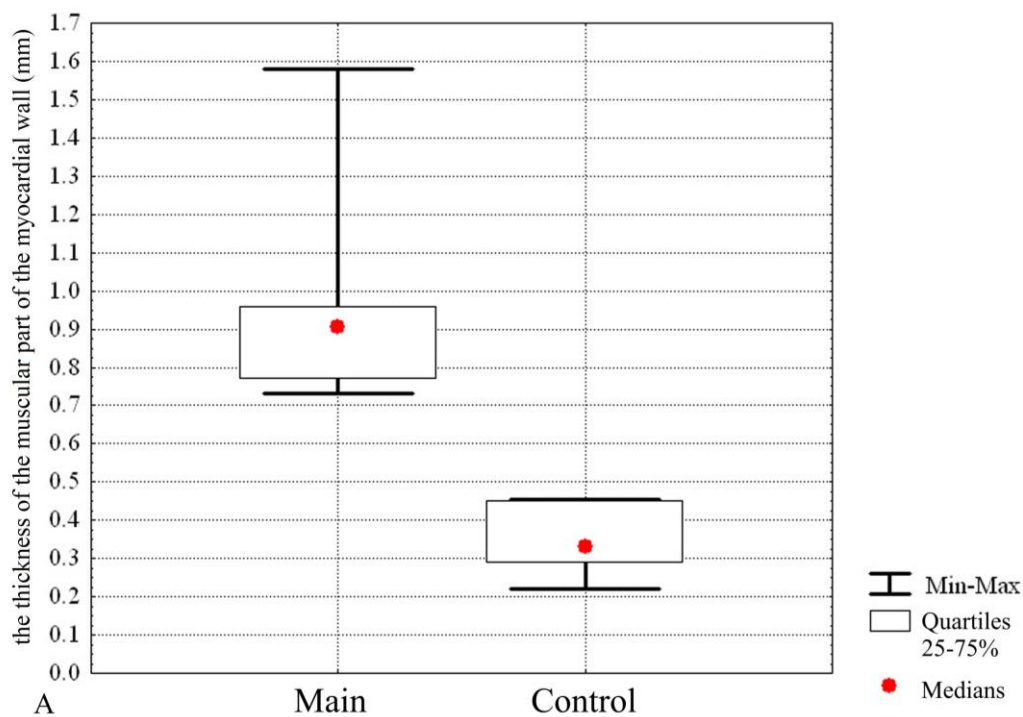


Figure 2. The thickness of the muscle wall in the experimental and control groups of rats was measured 45 days after the administration of saline solution. **A:** Experimental groups on the x-axis. The ordinate axis is the thickness of the muscular part of the myocardial wall (mm), **B:** Thickness of the myocardium of the left ventricle 45 days after the injection of allogeneic biomaterial in the experimental group, **C:** Wall of the left ventricle of the heart 45 days after the administration of saline solution in the control group. Main: The experimental group, Control: The control group. Van Gieson staining. Magnification X100.

The thickness of the rats' heart scars in the experimental group (0.382 μm) was slightly greater ($p < 0.05$) compared to that in the control group (0.355 μm). However, after statistical processing, the limits of variation in scar thickness for both groups almost overlap entirely, and the difference in medians proved to be insignificant ($p > 0.05$, $Z = 0.33$; Figure 3a). The difference in the diameter of the damaged myocardial zone in the experimental and control groups turned out to be statistically insignificant ($p > 0.05$, $Z = 0.73$). Simultaneously, the control group exhibited significant intragroup variability in scar thickness, with the maximum and minimum values differing by a factor of ten (Figure 3b).

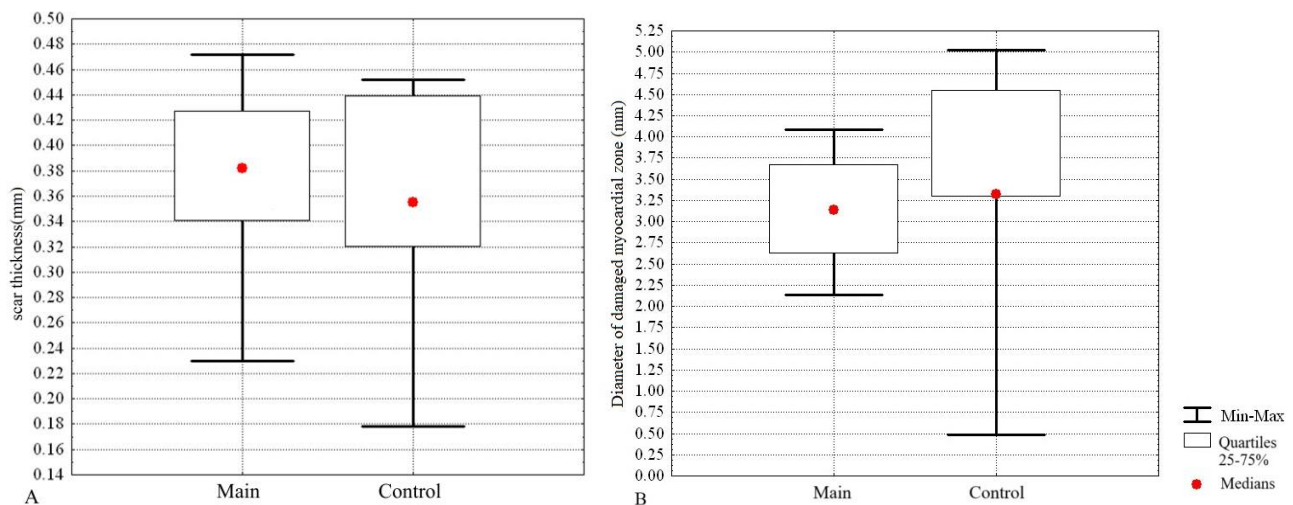


Figure 3. Left ventricular wall structure in rats after 45 days. **A:** Scar thickness (mm) of the left ventricle of experimental and control groups, **B:** Diameter of damaged myocardial zone (mm) of the experimental and control groups, Main: The experimental group, Control: The control group.

Analyzing the morphometric criteria of the scar at the site of cryogenic myocardial damage in the control group, 45 days after exposure to AB, indicated that the differences in the thickness of the scar itself and the diameter of the damaged area were not statistically significant ($p > 0.05$). However, the thickness of the muscular part of the left ventricular wall in the experimental group was significantly (Three orders of magnitude) higher than in the control group ($p > 0.05$).

Consequently, the use of AB in conditions of developed fibrous degeneration of the myocardium did not significantly affect its size. However, an increase ($p > 0.05$) in heart mass in the control group was indicative of cardiac hypertrophy. In contrast, the thickening of the muscular part of the left ventricular wall in the experimental group did not lead to heart mass changes. Scar reorganization and the appearance of cardiac muscle cells might be the result of a variety of signaling and immune responses initiated by the AB. It is known that AB promotes the transformation of dense fibrous tissue into loose tissue through the regulation of the ratio of metalloproteinases and their inhibitors (MMP-9/Timp-2), which are promoters and chemoattractants of progenitor cells, stimulate neoangiogenesis, and inhibit fibrosis (Lebedeva et al., 2018; 2023). The modifying effects of AB on the fibrous myocardium and the state of cardiomyocytes in the peri-scar zone would help improve the functional viability of the heart (Lebedeva et al., 2018; 2020; 2023). In the present study, it was observed that the modifying effect resulted in a significant increase ($p < 0.05$) in exercise tolerance in rats in the experimental group.

Thus, a single injection of AB into the formed myocardial scar that developed at the site of cryodestruction, after 45 days, initiated the transformation of dense, formed fibrous connective tissue into a connective tissue-muscle regenerate. After using the AB, cardiac muscle fibers were examined, which significantly improved their morphological picture and increased the load tolerance compared to the control group ($p > 0.05$).

DISCUSSION

Recent studies by Muldashev et al. (2005) and Rana et al. (2019) indicated that the use of biomaterials can promote tissue regeneration and improve cardiac function. Additionally, the use of collagen-based hydrogels in rats with myocardial infarction results in a significant improvement in ejection fraction and a reduction in fibrosis. Comparing the studied AB with materials used in other studies, such as collagen-based hydrogels, it is notable that AB demonstrated more pronounced angiogenesis (Muldashev et al., 2005; Yu, 2023). This may be due to the presence of growth factors in its composition that stimulate the formation of new vessels. In the present study, the AB was used, which was assumed to have similar regenerative properties. The studied AB had unique structural and biochemical properties that improved regenerative processes in the ischemic myocardium. In particular, the biocompatibility of AB and its porous structure

promoted cell migration and proliferation, as evidenced by the increase in the number of cardiomyocytes and stem cells in the damaged area (Lebedeva et al., 2018; 2020). When comparing the current results to the findings of Gallyamov et al. (2014) and Zhou et al. (2022), it is essential to acknowledge studies that utilized a distinct biomaterial, such as decomposed cardiac matrix. The findings of Gallyamov et al. (2014) and Zhou et al. (2022) indicated an improvement in the contractile function of the heart and a decrease in inflammatory processes. Functional improvements such as ejection fraction and contractility were not investigated in the present study, but observed data indicated a more pronounced decrease in fibrosis compared to the results of other studies (Gallyamov et al., 2014; Zhou et al., 2022). The present and previous studies confirmed the potential of AB in the treatment of chronic ischemic myocardial injury and indicated the need for further research to optimize its use and understand the mechanisms of its action (Lebedeva et al., 2018; 2020; 2023). Additionally, it is essential to consider the studies focused on the long-term effects of biomaterials. Although the findings of Muldashev et al. (2005), Zhou et al. (2022), and Lebedeva et al. (2023) demonstrated that some biomaterials can cause immune reactions with long-term use, in the current study, significant immune reactions weren't observed, suggesting the biocompatibility of the AB used in the short-term period.

Thus, the present study complemented the existing data on the use of biomaterials in the treatment of chronic ischemic myocardial injury, which suggested that AB is a promising therapeutic method to improve the morphological and functional characteristics of the rats' hearts.

CONCLUSION

Analysis of the presented results indicated the positive influence of allogeneic biomaterial on the structure of the myocardium in rats that have undergone cryogenic destruction. Morphological changes in the regenerated tissue, induced by allogeneic biomaterial, provided better functional capacity of the heart, which was manifested in a significant increase in the animals' tolerance to physical activity. This result may be due to the condition of the regenerated tissue, which was transformed under the influence of the allogeneic biomaterial's biodegradation products. It can be assumed that the use of an injectable form of dispersed AB would be effective for restoring the heart muscle after resection of a cardiac aneurysm or coronary bypass surgery. Based the current results, the following directions for further research can be highlighted as studies of a long-term effect of the AB, research on the different modifications of the AB, such as the addition of specific growth factors or changes in its structural properties to improve its regenerative capabilities, in-depth comparative studies on different biomaterials and clinical trials of the studied AB.

DECLARATIONS

Acknowledgments

The authors would like to acknowledge the Federal State Budgetary Scientific Institution, All-Russian Research Veterinary Institute of Pathology, Pharmacology and Therapy, Ufa, Russia, and the Federal State Budgetary Educational Institution of Higher Education, Saint Petersburg State University of Veterinary Medicine, Saint Petersburg, Russia.

Authors' contributions

Lebedeva Anna and Musina Lyalya designed the experiment, worked with the animals, and wrote the manuscript. Prusakov Alexey conducted the histological examination and sample preparation, as well as the literature review and manuscript writing. Ponamarev Vladimir conceptualized the manuscript, revised, translated, and performed the statistical analysis. All authors confirmed the last edition of the article before submission to the journal.

Competing interests

The authors declared no conflict of interest.

Ethical considerations

This study was originally written by the authors and has not been published elsewhere. The authors checked the text of the article for plagiarism index and confirmed that the text of the article is written based on their original scientific results.

Availability of data and materials

The data to support the present findings of the study is available upon reasonable request from the corresponding author.

Funding

This study did not receive any financial support.

REFERENCES

- Adamyan LV, Burgova EN, Serezhenkov VA, Zairatyants OV, Arslanyan KN, Sonova MM, Guliyev MT, and Maksimova YV (2011) Method of anesthesia in rats in a multi-stage experiment in modeling endometriosis. Patent, № RU2466753C1. Available at: <https://patents.google.com/patent/RU2466753C1/en>
- Afanasiev SA, Rogovskaya UV, Falaleeva LP, Sviridov IN, Shakhov VP, and Popov SV (2009). Comparative assessment of heart remodeling in rats after experimental coronary stenosis and cryodestruction. *Bulletin of Experimental Biology and Medicine*, 147(6): 695-697. DOI: <https://www.doi.org/10.1007/s10517-009-0602-3>
- Alekhin YuN, Popova OS, Ponamarev VS, and Parshin PA (2023). The effect of farnesoid X receptor agonist on postprandial lipemia in rats receiving a diet containing a supraphysiological dose of fats. *Development and Registration of Drugs*, 12(2): 174-184. DOI: <https://www.doi.org/10.33380/2305-2066-2023-12-2-174-184>
- Algoet M, Janssens S, Himmelreich U, Gsell W, Pusovnik M, Van den Eynde J, and Oosterlinck W (2023). Myocardial ischemia-reperfusion injury and the influence of inflammation. *Trends in Cardiovascular Medicine*, 33(6): 357-366. DOI: <https://www.doi.org/10.1016/j.tcm.2022.02.005>
- Baryshev VA, Popova OS, and Ponamarev VS (2022). New methods for detoxification of heavy metals and mycotoxins in dairy cows. *Online Journal of Animal and Feed Research*, 12(2): 81-88. DOI: <https://www.doi.org/10.51227/ojafr.2022.11>
- Can A, Dao DT, Arad M, Terrillion CE, Piantadosi SC, Gould TD (2012). The mouse forced swim test. *Journal of Visualized Experiments*, 29(59): e3638. DOI: <https://www.doi.org/10.3791/3638>
- Chen Y, Liu S, Liang Y, He Y, Li Q, Zhan J, Hou H, and Qiu X (2024). Single dose of intravenous miR199a-5p delivery targeting ischemic heart for long-term repair of myocardial infarction. *Nature Communications*, 15(1): 5565. DOI: <https://www.doi.org/10.1038/s41467-024-49901-x>
- Fácila Rubio L, Lozano-Granero C, Vidal-Pérez R, Barrios V, and Freixa-Pamias R (2024). New technologies for the diagnosis, treatment, and monitoring of cardiovascular diseases. *Revista Española de Cardiología*, 77(1): 88-96. DOI: <https://www.doi.org/10.1016/j.rec.2023.07.009>
- Gallyamov MO, Chaschin IS, Khokhlova MA, Grigorev TE, Bakuleva NP, Lyutova IG, Kondratenko JE, Badun GA, Chernysheva MG, and Khokhlov AR (2014). Collagen tissue treated with chitosan solutions in carbonic acid for improved biological prosthetic heart valves. *Materials Science and Engineering: C*, 37: 127-140. DOI: <https://www.doi.org/10.1016/j.msec.2014.01.017>
- Garganeva AA, Okrugin SA, and Borel KN (2015). World health organization program “registry of acute myocardial infarction: Capabilities and prospects for studying and predicting outcomes of socially significant diseases. *Siberian Journal of Clinical and Experimental Medicine*, 30(2): 125-130. DOI: <https://www.doi.org/10.29001/2073-8552-2015-30-2-125-130>
- Johnstone BH, Gu D, Lin CH, Du J, and Woods EJ (2023). Identification of a fundamental cryoinjury mechanism in MSCs and its mitigation through cell-cycle synchronization prior to freezing. *Cryobiology*, 113: 104592. DOI: <https://www.doi.org/10.1016/j.cryobiol.2023.104592>
- Karkishchenko VN, Kapanadze GD, Dengina SE, and Stankova NV (2011). Development of methods for assessing the physical endurance of small laboratory animals for the study of adaptogenic activity of certain drugs. *Biomedicine*, 1(1): 72-74. Available at: <https://journal.scbmt.ru/jour/article/view/631/478>
- Kruglyakov PV, Sokolova IB, Amineva KhK, Nekrasova NN, Viide SV, Cherednichenko NN, Zaritsky AY, Semernin EN, Kislyakova TV, and Polyntsev DG (2004). Therapy of experimental myocardial infarction in rats using syngeneic mesenchymal stem cell transplantation. *Cytology*, 46(12): 1043-1054. Available at: http://tsitologiya.incras.ru/46_12/kruglyakov_ru.htm
- Kuznetsov YuE, Lunegov AM, Ponomarev VS, and Romashova EV (2022). Correlation relationships between the content of total bile acids and the main biochemical parameters of blood in minks (*Mustela vison* Schreber, 1777). *Agricultural Biology*, 57(6): 1217-1224. DOI: <https://www.doi.org/10.15389/agrobiol.2022.6.1217rus>
- Lebedeva AI, Gareev EM, Afanasyev SA, Kondratyeva DS, Muslimov SA, and Popov SV (2023). Allogeneic biomaterial - an inhibitor of fibrosis in ischemically damaged myocardium. *Medical Immunology*, 25(2): 301-308. DOI: <https://www.doi.org/10.15789/10.15789/1563-0625-ABA-2359>
- Lebedeva AI, Muslimov SA, Gareev EM, Afanasiev SA, Condratyeva DS, and Popov SV (2020). Macrophages as homeostatic regulators in the ischemically damaged myocardium after use of allogenic biomaterial. *Bulletin of Siberian Medicine*, 19(1): 67-75. DOI: <https://www.doi.org/10.20538/1682-0363-2020-1-67-75>
- Lebedeva AI, Muslimov SA, Gareev EM, Popov SV, Afanasyev SA, and Kondratyeva DS (2018). Expression of metalloproteinases and their inhibitors in the ischemic myocardium after the use of allogeneic biomaterial. *Russian Journal of Cardiology*, 23(7): 73-79. DOI: <https://www.doi.org/10.15829/1560-4071-2018-7-73-79>
- Maurya CS and Kumar A (2025) Modelling of coronary artery stenosis and study of hemodynamic under the influence of magnetic fields. *Computers in Biology and Medicine*, 184: 109464. DOI: <https://www.doi.org/10.1016/j.combiomed.2024.109464>
- Muldashev ER, Muslimov SA, Musina LA, Nigmatullin RT, Lebedeva AI, Shangina OR, and Khasanov RA (2005). The role of macrophages in the tissue regeneration stimulated by the biomaterials. *Cell and Tissue Banking*, 6(2): 99-107. DOI: <https://www.doi.org/10.1007/s10561-004-5805-2>
- Ponomarev V, Popova O, Kostrova A, and Agafonova L (2023a). A new method for assessing the toxic properties of various medicinal substances on the hepatobiliary system functionality in the context of ecopharmacology development. II International Conference Sustainable Development: Agriculture, Veterinary Medicine, and Ecology, Karshi, 3011: 20027. DOI: <https://www.doi.org/10.1063/5.0161091>
- Ponomarev V, Popova O, Kostrova A, and Agafonova L (2023b). The concept of development of new ecologically based methods of diagnostics and pharmacocorrection in veterinary medicine (on the example of pathologies of the hepatobiliary system). II

- International Conference Sustainable Development: Agriculture, Veterinary Medicine and Ecology, Karshi, 3011: 20028. DOI: <https://www.doi.org/10.1063/5.0161092>
- Prusakova A, Zelenevskiy N, Prusakov A, Yashin A, and Ponamarev V (2023a). Organization of histo-hematic barriers of the liver in Anglo-Nubian. Online Journal of Animal and Feed Research, 13(4): 242-245. DOI: <https://www.doi.org/10.51227/ojafr.2023.36>
- Prusakova AV, Zelenevskiy NV, Prusakov AV, Yashin A, and Ponamarev V (2023b). Ultrastructural organization of liver hepatocytes of the Anglo-Nubian goat. Veterinarski Glasnik, 77(2): 176-187. DOI: <https://www.doi.org/10.2298/VETGL230615007P>
- Rana MM, Rahman MS, Ullah MA, Siddika A, Hossain ML, Akhter MS, Hasan MZ, and Asaduzzaman SM (2019). Amnion and collagen-based blended hydrogel improves burn healing efficacy on a rat skin wound model in the presence of wound dressing biomembrane. Bio-Medical Materials and Engineering, 31(1): 1-17. DOI: <https://www.doi.org/10.3233/BME-201076>
- Shutsky NA, Shagrov LL, Kashutin SL, Aksenov AS, and Malyavskaya SI (2019). Dynamics of collagen content in the dermis of rats after local cold damage. Proceedings of the Karelian Research Center of the Russian Academy of Sciences, 6: 85-91. DOI: <https://www.doi.org/10.17076/eb967>
- Yanin VL, Bondarenko OM, and Sazonova NA (2015). Study guide for full-time postgraduate students for practical classes in the discipline research methods in cytology and histology. Khanty-Mansiysk, Russia, pp. 8-38. Available at: https://hmgma.ru/sveden/docs/uchebno-metod_aspir_issled%20gistolog%20ochn.pdf
- Yu X (2023) Application of hydrogels in cardiac regeneration. Cardiology and Therapy, 12(4): 637-674. DOI: <https://www.doi.org/10.1007/s40119-023-00339-0>
- Zhou Y, Zhang XL, Lu ST, Zhang NY, Zhang HJ, Zhang J, and Zhang J (2022). Human adipose-derived mesenchymal stem cells-derived exosomes encapsulated in pluronic F127 hydrogel promote wound healing and regeneration. Stem Cell Research & Therapy, 13(1): 407. DOI: <https://www.doi.org/10.1186/s13287-022-02980-3>

Publisher's note: Scienceline Publication Ltd. remains neutral with regard to jurisdictional claims in published maps and institutional affiliations.



Open Access: This article is licensed under a Creative Commons Attribution 4.0 International License, which permits use, sharing, adaptation, distribution and reproduction in any medium or format, as long as you give appropriate credit to the original author(s) and the source, provide a link to the Creative Commons licence, and indicate if changes were made. The images or other third party material in this article are included in the article's Creative Commons licence, unless indicated otherwise in a credit line to the material. If material is not included in the article's Creative Commons licence and your intended use is not permitted by statutory regulation or exceeds the permitted use, you will need to obtain permission directly from the copyright holder. To view a copy of this licence, visit <https://creativecommons.org/licenses/by/4.0/>.

© The Author(s) 2025